
Correspondence and Brief Communications

Correspondence and brief communications are welcomed and need not concern only what has been published in this journal. We shall print items of interest to our readers, such as experimental, clinical, and philosophical observations; reports of work in progress; educational notes; and travel accounts relevant to plastic surgery. We reserve the right to edit communications to meet requirements of space and format. Any financial interest relevant to the content of the correspondence must be disclosed. Submission of a letter constitutes permission for the American Society of Plastic and Reconstructive Surgeons and its licensees and assignees to publish it in the journal and in any other form or medium.

The views, opinions, and conclusions expressed in the Letters to the Editor represent the personal opinions of the individual writers and not those of the publisher, the Editorial Board, or the sponsors of the journal. Any stated views, opinions, and conclusions do not reflect the policy of any of the sponsoring organizations or of the institutions with which the writer is affiliated, and the publisher, the Editorial Board, and the sponsoring organizations assume no responsibility for the content of such letters.

WHY CLIMB A LADDER WHEN YOU CAN TAKE THE ELEVATOR?

Sir:

We would like to draw attention to the *Journal's* June 1994 Editorial, "From the Reconstructive Ladder to the Reconstructive Elevator."¹ Since its publication, the concept of the reconstructive ladder (Fig. 1) continues to be taught and appears in current textbooks, but without reference to the ingenious concept of the reconstructive elevator (Fig. 2).

In our quest to provide optimal form and function, it should currently be acceptable to jump several rungs of the ladder, with the knowledge that some defects require more complex solutions. Accepting that the ladder represented an oversimplification of the decision-making process, Mathes and Nahai proposed a new paradigm, the "reconstructive triangle."² The three corners of the triangle represented flaps, microsurgery, and tissue expansion. Although this gave microsurgery and tissue expansion their deserved consideration, it ignored the ascending concept of the ladder that encourages the surgeon to consider reconstructive options in order of complexity.

The reconstructive elevator allows one to ascend from the simplest to the more complex techniques, with the freedom to ascend directly to the chosen level of complexity. Clearly, this decision will be based upon the needs of the patient, together with the knowledge, experience, and technical ability of the surgeon and the multidisciplinary team. It will ensure the use of the most appropriate surgical option necessary to reconstruct the defect, resulting in optimal restoration of form and function for the patient, and it will encourage parallel, creative thought, as recommended by the authors of the editorial.

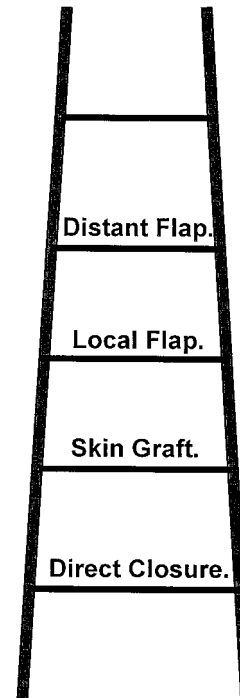


FIG. 1. The reconstructive ladder.

We believe that the idea of the reconstructive elevator recognizes changes that have been made in the art and science of plastic surgery. Many of these changes have occurred in recent decades; as experience has been gained, they have become safe and reliable and are no longer considered a last resort. The elevator demonstrates an evolution in thinking that parallels the advanced techniques and progressive technology we are witnessing in our field today. We hope that our diagram will help broaden its acceptance, particularly by plastic surgeons in training.

Nicholas Bennett, M.B., B.S., F.R.C.S.(Lond.)

Sunil Choudhary, M.S., F.R.C.S.(Ed.)

Odstock Centre for Burns, Plastic and Maxillo-facial Surgery
Salisbury District Hospital

Odstock Road

Salisbury SP2 8BJ, England

United Kingdom

REFERENCES

1. Gottlieb, L. J., and Krieger, L. M. From the reconstructive ladder to the reconstructive elevator (Editorial). *Plast. Reconstr. Surg.* 93: 1503, 1994.
2. Mathes, S. J., and Nahai, F. *Reconstructive Surgery: Principles, Anatomy, and Technique*. London: Churchill Livingstone, 1997. Pp. 11-12.

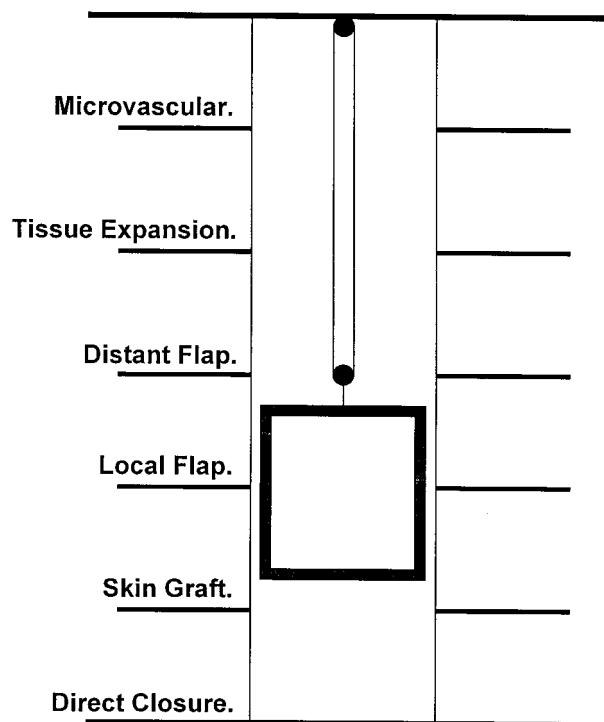


FIG. 2. The reconstructive elevator.

BREAST MILK LIDOCAINE LEVELS IN TUMESCENT LIPOSUCTION

Sir:

Although lidocaine excretion in breast milk has been previously reported,¹ we are unaware of any accounts of breast milk lidocaine levels after tumescent liposuction. In the research of Zeisler et al.,¹ the patient received 720 mg of lidocaine by intravenous bolus. The breast milk lidocaine level was drawn 7 hours after the intravenous bolus, and the breast milk lidocaine level was measured as 40 percent of the serum lidocaine level. We report the first case of lidocaine levels in breast milk from a nursing mother undergoing tumescent liposuction and discuss the potential implications for a nursing infant.

Because of Klein's pioneering work,² lidocaine is currently used at a much higher concentration during tumescent liposuction than the alleged maximum level of 7 mg/kg.³ The acceptable range of lidocaine levels used during tumescent liposuction is surgeon-dependent and ranges from 35 to 90 mg/kg.^{2,4,5} Although lidocaine was not previously thought to be excreted in breast milk, it has been found in the milk of a nursing mother and comprised 40 percent of the serum level.¹ Because there is no report in the literature of lidocaine excretion into the milk of a nursing mother and because the pharmacokinetics of lidocaine absorption are different in tumescent liposuction than in an intravenous bolus, we wished to determine the excretion of lidocaine in the milk from a nursing mother undergoing tumescent liposuction.

A 31-year-old, 80-kg nursing mother underwent tumescent liposuction of her abdomen, flanks, hips, back, and submental areas. A preoperative cocktail of 10 mg oral Valium, 0.1 mg oral Clonidine, 25 mg intramuscular Phenergan, and 50 mg intramuscular Demerol was administered. Intraoperatively, the patient received 1 mg intravenous Versed and 100 mg of intravenous Demerol. The areas undergoing liposuction

were infiltrated with tumescent solution prepared by mixing 1 liter of normal saline, 50 cc of 1% lidocaine, 12.5 cc of 8.4% sodium bicarbonate, 1 cc of 1:1000 epinephrine, and 0.25 cc of Triamcinolone. A total of 8400 cc of tumescent solution was infiltrated into the patient's fat, giving a lidocaine concentration of 52.5 mg/kg. The mother had previously elected not to nurse during the 3-day period after tumescent infusion.

We drew the patient's blood 18 hours after the procedure; she had manually expressed milk about an hour before collection of blood. The serum and milk were assayed for lidocaine at the National Medical Services Laboratory (Willow Grove, Pa.) using gas chromatography.

The patient's lidocaine concentration in the breast milk was 0.55 $\mu\text{g}/\text{ml}$, whereas the serum level was 1.2 $\mu\text{g}/\text{ml}$. The breast lidocaine concentration was 46 percent of the serum level, similar to the 40 percent previously reported.¹

Although nursing mothers rarely present for liposuction, it is desirable to know the amount of lidocaine present in breast milk after tumescent liposuction if the mother is interested in continuing nursing during the postoperative period. A previous report showed that lidocaine is expressed in breast milk.¹ In this report, the blood was drawn 5 hours after 720 mg of IV lidocaine was given; the milk was collected 2 hours later. The serum lidocaine level was 2.0 $\mu\text{g}/\text{ml}$, and the breast milk lidocaine level was 0.8 $\mu\text{g}/\text{ml}$. This is the second published report showing that breast milk lidocaine levels are approximately 40 to 45 percent of the serum levels.

Our patient received 4200 mg of lidocaine through her tumescent procedure. Her serum lidocaine and breast milk lidocaine levels were obtained 18 hours after completion of surgery. Klein and Lillis' work showed that lidocaine infused by the tumescent technique peaks around this time postoperatively.^{2,4,5} It is interesting to note that despite the large dose of lidocaine administered by the tumescent technique, the serum level was 1.2 $\mu\text{g}/\text{ml}$, which is similar to Klein's original findings.² A therapeutic lidocaine level for antiarrhythmic indications is 1.5 to 5 $\mu\text{g}/\text{ml}$; our patient's lidocaine level was significantly below the toxicity level.⁶

The question arises as to potential risk to the nursing infant. Orally administered lidocaine undergoes first-pass metabolism in the adult, and the bioavailability of lidocaine after ingestion ranges from 30 to 35 percent.^{7,8} This level is assumed to be similar for infants. If our patient's infant were to consume 90 ml of breast milk every 3 hours, the infant would ingest only 396 μg of lidocaine per day, of which only 30 percent would be bioavailable. A 5-kg infant with an assumed 30 percent bioavailability would have a lidocaine concentration of 26.4 $\mu\text{g}/\text{kg}$. In a 10-kg infant, this level would be half that of the 5-kg infant. These levels reflect an extremely miniscule amount of lidocaine that should not present problems of toxicity for the infant; they are calculated on the false assumption that, in a 1-day period, lidocaine would stay at peak level for 24 hours. Furthermore, the amount of lidocaine in the breast milk would diminish daily as the mother cleared lidocaine from her body. There is also the possibility of an idiosyncratic reaction to the lidocaine, which has been reported in the adult but not the pediatric literature.^{9,10}

The tumescent liposuction technique has demonstrated its safety by limiting high serum lidocaine levels when used as described by Klein or Lillis.^{2,4,5} With the breast lidocaine level being approximately 45 percent of the serum level and with its limited bioavailability, it is unlikely that the infant would reach toxic levels by continued nursing after tumescent liposuction of the mother.

Robert M. Dryden, M.D.
Mikel W. Lo, M.D.
Arizona Centre for Plastic Surgery
1241 N. Wilmot Road
Tucson, Ariz. 85712

REFERENCES

1. Zeisler, J. A., Gaarder, T. D., and DeMesquita, S. A. Lidocaine excretion in breast milk. *Drug Intell. Clin. Pharm.* 20: 691, 1986.
2. Klein, J. A. Anesthesia for liposuction in dermatologic surgery. *J. Dermatol. Surg. Oncol.* 14: 1124, 1988.
3. Arky, R. *Physician's Desk Reference*, 53rd Ed. Montvale, N. J.: Medical Economics, 1999. P. 605.
4. Meusch, R., and Lillis, P. J. Liposuction: The tumescent technique. *Dermatol. Nurs.* 3: 255, 1991.
5. Lillis, P. J. The tumescent technique for liposuction surgery. *Dermatol. Clin.* 8: 439, 1990.
6. Hardman, J. G., and Limbird, L. E. (Eds.). *Goodman and Gilman's The Pharmacologic Basis of Therapeutics*, 9th Ed. New York: McGraw-Hill, 1996. P. 867.
7. DeBoer, A. G., Breimer, D. D., Mattie, H., Pronk, J., and Gubbens-Stibbe, J. M. Rectal bioavailability of lidocaine in man: Partial avoidance of "first pass" metabolism. *Clin. Pharmacol. Ther.* 26: 701, 1979.
8. Ritschel, W. A., Elconin, H., Alcor, G. J., and Denson, D. D. First-pass elimination of lidocaine in the rabbit after peroral and rectal route of administration. *Biopharm. Drug Dispos.* 6: 281, 1995.
9. Hoffmann, H., Maibauch, H. I., and Prout, E. Exfoliative dermatitis following injection of 2% lidocaine as a dental anesthetic (Letter). *Arch. Dermatol.* 111: 266, 1975.
10. O'Donohue, W. J. Acute methemoglobinemia induced by topical benzocaine and lidocaine. *Arch. Intern. Med.* 140: 1508, 1980.

LIPOSUCTION WITH STANDING TECHNIQUE

Sir:

I read with great interest the article by Shuter and Drourr¹ regarding liposuction with the standing technique. Almost all physicians performing liposuction premark the patient in the standing position, then attempt to remove the fat in areas that have changed position once the patient is supine. In combination with palpation and visual recall of the patient's abnormal fat deposits, we liposuction fat and get a reasonable improvement in the body contours. A patient in the standing position would certainly give the surgeon a better view of the abnormal fat deposits during surgery.

In 1992, Fischer² developed an orthostatic liposculpture operating table that permitted the patient to be moved from the horizontal to the vertical position during the liposuction procedure. By 1993, the table was improved to provide electronic control of the table movement, a rotating safety sling to secure the patient, and a footrest to sustain the patient's weight. Fischer³ had already lectured on the orthostatic technique.

In 1996, Botti⁴ described the technique of having the patient stand to check and refine the results as being a simple process. However, the patient must be under local anesthesia to ensure their cooperation and a central line must be used in the event of an emergency.

An important aspect of using the orthostatic technique is

understanding the seriousness of hypotension and the need for immediate treatment. The treatment of choice is to initially place the patient in a supine position. This is not done by Shuter and Drourr,¹ who prefer to place the patient in a sitting position and use intravenous fluids and epinephrine. Fischer's orthostatic table promptly allows the patient to be placed supine, without the need for increased fluids or epinephrine.² Preoperative fluid loading as used by Shuter and Drourr¹ is unnecessary because intravenous saline or Ringer's lactate remains in the vascular system for only 15 minutes. When large amounts of tumescent solution are used, increasing intravenous fluids for treatment of a vasovagal reflex may result in fluid overload.

Shuter and Drourr used a wet technique of 500 to 1000 cc of fluid, then aspirated from 1000 to 2800 cc of fat and fluid. This resulted in more blood loss (up to 30 percent) than necessary. The preferred technique to aspirate with tumescent solution is 1:1 or 2:1, which brings blood loss down to about 1 to 5 percent of the fluid aspirate.

Melvin A. Shiffman, M.D.
1101 Bryan Avenue, Suite G
Tustin, Calif. 92780

REFERENCES

1. Shuter, D., and Drourr, N. R. Liposuction with standing technique: The true lipo "sculpture." *Plast. Reconstr. Surg.* 104: 1546, 1999.
2. Fischer, G. Orthostatic liposculpture. *Am. J. Cosmetic Surg.* 12: 211, 1995.
3. Fischer, G. Orthostatic Technique. Presented at the International Congress of the International Society of Aesthetic Surgery, Tokyo, 1985.
4. Botti, G. Orthostatic liposculpture (Correspondence). *Am. J. Cosmetic Surg.* 13: 168, 1996.

REPLY

Sir:

It was certainly a great honor to have my article published in the October 1999 issue of the *Journal*. The response has been quite flattering, with several physicians around the country requesting more specific details. I write this letter in response to the above and hope to clear up some misconceptions.

In response to Dr. Shiffman's letter, it is clear that his thinking parallels my own. We have both come to the same conclusion—that the standing position presents many advantages for intraoperative sculpting during liposuction. Although the above techniques of local anesthesia and an "orthostatic liposculpture operating table" do provide an option, they seem to be complicated and unwieldy. A purely sensory epidural technique provides the answer—appropriate anesthesia with decreased risk, discomfort, and postoperative problems. The success of this technique obviously depends on the skill of the anesthesiologist, with regard to placement, choice of agent, and titration during the procedure.

Regarding Dr. Shiffman's concern about the dangers of hypotension, we are certainly in agreement. However, he is incorrect in his statement on treatment, at least in the case of our procedure. With our preoperative fluid protocol and carefully monitored epidural, incidence of hypotension has decreased and, as described in our article, has been treated easily with fluid and pressor agents. If necessary, the patient can be placed supine in a matter of seconds, although this has

not been needed even once in 2 years of performing this technique.

In conclusion, I certainly appreciate Dr. Shiffman's comments and interest. I also note that his letterhead describes him as a "general surgeon" and a "cosmetic and reconstructive surgeon," rather than as a fully trained plastic and reconstructive surgeon. I cannot comment on Dr. Shiffman's techniques because he does not present them. However, I perform all of my liposuction procedures in a hospital setting using physician anesthesiologists and all appropriate, hospital-based monitoring and resuscitation available. I do not "stretch the limits of safety" by performing large volumes of aspiration with a standing technique, and I do not "overload" with excessive tumescent solution. I wonder if Dr. Shiffman can say the same?

David Shuter, M.D.
1025 Military Trail, Suite 107
Jupiter, Fla. 33458

IMPORTANCE OF THE PEDICLE LENGTH MEASUREMENT IN REDUCTION MAMMAPLASTY

Sir:

I would like to respond to the article in the August 1999 issue by Jackson et al. on the importance of pedicle length measurement in reduction mammoplasty (*Plast. Reconstr. Surg.* 104: 398, 1999).

Dr. Jackson, whose expertise is well appreciated, concluded in his abstract that the free nipple graft technique need never be considered. I take offense to this because there is no reduction mammoplasty that cannot be done with the inferior technique. However, there are some elderly women in their mid-seventies who have significant mammary hyperplasia and who wish to be made very small, in the B-cup range. It is my impression that to attempt preservation of nipple areolar circulation and sensation with a pedicle of any kind would be impossible in extremely large breasts, because folding of the pedicle itself would result in volume greater than a B cup. A number of my patients have requested the change from a DDD to a B cup. These, of course, are not the younger patients, but the elderly ladies who have significant problems with osteoarthritis, etc., and who have the greatest symptoms from mammary hyperplasia.

I thank you for accepting this letter because I feel there are indications, although rare, for the free nipple graft technique in reduction mammoplasty.

Ronald G. Worland, M.D.
Plastic Surgery Specialists, P.C.
2959 Siskiyou Blvd.
Suite A
Medford, Ore. 97504-1907

REPLY

Sir:

I know that Dr. Worland has a lot of experience in breast reduction, particularly in the reduction of large breasts, but I don't ever recall having had the clinical situation that he describes. In our society, it is rare to have ladies of that age request breast surgery. Therefore, I would concede in that situation that there may be a case for free nipple graft, but I think that even then I would use that option only if I was unable to meet the patients requirements with the standard technique. Furthermore, I am very impressed at how narrow

the pedicle can be made and at how much tissue can be sacrificed superiorly, laterally, and medially in the main portion of the breast. I also agree that "never" is rather a strong term in relation to any surgical procedure.

Ian T. Jackson, M.D., D.Sc.(Hon.), F.R.C.S., F.R.A.C.S.(Hon.)
Institute for Craniofacial and Reconstructive Surgery
Providence Hospital
16001 West Nine Mile Road
3rd Floor Fisher Center
Southfield, Mich. 48075

REFINED VERSION OF THE TUBEROUS BREAST CLASSIFICATION

Sir:

In 1996, we published a classification system on tuberous breast deformity in the *British Journal of Plastic Surgery*.¹ There was great interest in the classification and many surgeons wrote to us. The classification system was cited in *Breast Diseases: A Year Book Quarterly* in 1997² and in *The Year Book of Plastic, Reconstructive, and Aesthetic Surgery* in 1998.³ The positive response that it received gave us the impression that the responding surgeons work with the classification. We also received some helpful advice suggesting that because no profile view of the classified types of deformity was presented, it was more difficult to understand the classification. The reviews encouraged us to refine the schemes of types I through IV and to submit a better quality.

A refined version (Fig. 1) of this scheme is presented that is more applicable to treatment of the tuberous breast. In our hands, the individual type can now be easily classified.⁴ We hope for its widespread acceptance and use, especially in the preoperative classification of breast deformities. This would be helpful in comparing postoperative results of surgeries performed by different surgeons using different techniques.

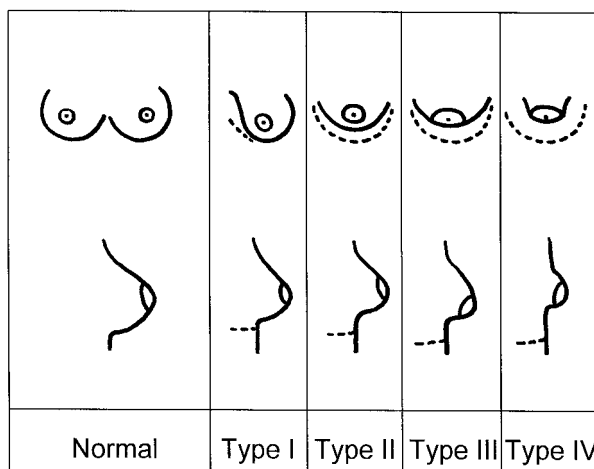


FIG. 1. Classification of the tuberous breast deformity. The higher the type of deformity, the higher the severity. Type I, hypoplasia of the lower medial quadrant; Type II, hypoplasia of the lower medial and lateral quadrants, sufficient skin in the subareolar region; Type III, hypoplasia of the lower medial and lateral quadrants, deficiency of skin in the subareolar region; Type IV, severe breast constriction, minimal breast base.

Dennis von Heimburg, M.D.
 Department of Plastic Surgery and Hand Surgery—Burn Center
 University Hospital, University of Technology Aachen
 Pauwelsstr. 30
 D-52057 Aachen
 Germany
 d.v.heimburg@plastchir.rwth-aachen.de

REFERENCES

1. von Heimburg, D., Exner, K., Krufft, S., and Lemperle, S. The tuberous breast deformity: Classification and treatment. *Br. J. Plast. Surg.* 49: 339, 1996.
2. von Heimburg, D., Exner, K., Krufft, S., et al. The tuberous breast deformity: Classification and treatment. *Breast Diseases: A Year Book Quarterly* 8: 177, 1997.
3. von Heimburg, D., Exner, K., Krufft, S., et al. The Tuberous Breast Deformity: Classification and Treatment. In S. H. Miller (Ed.), *The Year Book of Plastic, Reconstructive, and Aesthetic Surgery*, 1998 Ed. St. Louis: Mosby, 1998.
4. von Heimburg, D., Exner, K., and Pallua, N. Operative Application of the Tuberous Breast Classification Regarding Minimal External Scarring. In *Proceedings of the 12th Congress of the International Confederation for Plastic, Reconstructive, and Aesthetic Surgery*, San Francisco, June 27–July 2, 1999.

COAGULATED BLOOD WITHIN A REPLACED INTACT SILICONE GEL BREAST IMPLANT

Sir:

We report the case of a patient in whom coagulated blood was found within an apparently intact silicone gel breast implant. After a review of the literature, we propose a mechanism for how this may have occurred.

A 45-year-old woman had bilateral, smooth-walled, 270-cc silicone, noncohesive, gel-filled breast implants placed in the retropectoral plane for bilateral breast hypoplasia. Her operation was in 1988, and she was discharged from follow-up at 6 months.

Nine years later, she developed a firmness of the breasts that lasted for 6 months. Examination revealed a Baker IV capsular contracture of the left breast and a Baker III capsular contracture of the right breast. Upon counseling, it was decided to replace the implants after capsulectomies.

During the operation, it was noted that, although both of the implants appeared intact, there was a collected brown substance within the left breast implant (Fig. 1). No defect was seen in the implant wall and squeezing the implant caused none of the silicone to extrude. A peroxidase test on a sample of the brown substance showed it to be compatible with blood. No cells were seen on microscopy, suggesting that the blood had degraded.

The presence of what we presume to be coagulated blood within an apparently intact implant was rather surprising. In the absence of an obvious implant shell defect, we presume that a microscopic hole allowed the less viscous blood to enter the implant but did not allow the more viscous silicone gel to migrate out of it.

We reviewed the literature to find out more mechanisms by which various substances can enter implants. Most reports covered saline implants or expanders.^{1,2} Migration of microbes¹ into implants can be from contamination during the manufacturing process or when filling the implant/expander, either intraoperatively or postoperatively.² The por-



FIG. 1. The removed, intact silicone gel breast implant with brown material inside the implant.

tal of entry for microbes was thought to be through the filling port itself,^{3,4} but the passage of bacterial toxins has been reported through the implant shell, possibly by diffusion, although the mechanism remains unclear.^{4,5} Passage of microbes or toxins has only been reported in saline-filled implants, gel presumably being a poor culture medium.⁶

We report a patient who was found to have coagulated blood within a silicone gel breast implant during surgery to correct capsular contracture. Presumably, blood or hematoma had gained access to the lumen of the implant either by diffusion or through a small defect in the implant wall, without any apparent leakage of silicone gel.

Milind Dalal, M.B.B.S., M.S., M.Ch.(Plast.), F.R.C.S.
 George Eliot Hospital, Nuneaton
 Warwickshire, United Kingdom

Mark Cooper, M.B.B.S., F.R.C.S., F.R.C.S.(Plast.)
 Welsh Centre for Burns and Plastic Surgery
 Morriston Hospital, Morriston
 Swansea, United Kingdom

D. A. Munnoch, F.R.C.S.
 Whiston General Hospital, Prescot
 Merseyside, United Kingdom

REFERENCES

1. Young, V. L., Hertl, M. C., Murray, P. R., Jensen, J., Witt, H., and Schorr, M. W. Microbial growth inside saline-filled breast implants. *Plast. Reconstr. Surg.* 100: 182, 1997.
2. Rosenblatt, W. B., and Pollock, A. *Aspergillus flavus* cultured from a saline-filled implant (Letter). *Plast. Reconstr. Surg.* 99: 1470, 1997.
3. Young, V. L., Hertl, M. C., Murray, P. R., and Lambros, V. S. *Paecilomyces variotii* contamination in the lumen of a saline-filled breast implant. *Plast. Reconstr. Surg.* 96: 1430, 1995.
4. Chen, N. T., Butler, P. E., Hooper, D. C., and May, J. W., Jr. Bacterial growth in saline implants: In vitro and in vivo studies. *Ann. Plast. Surg.* 36: 337, 1996.
5. Niazi, Z. B., Salzberg, C. A., and Petro, J. A. *Paecilomyces variotii* contamination in the lumen of a saline-filled breast implant. *Plast. Reconstr. Surg.* 98: 1323, 1996.
6. Ahn, C. Y., Ko, C. Y., Wagar, E. A., Wong, R. S., and Shaw, W. W. Microbial evaluation: 139 implants removed

from symptomatic patients. *Plast. Reconstr. Surg.* 98: 1225, 1996.

LATISSIMUS DORSI DONOR-SITE QUILTING: LESS IS MORE?

Sir:

Donor-site seroma is a common problem after raising the latissimus dorsi myocutaneous flap for breast reconstruction. A modified method of quilting the donor-site flaps, resulting in zero clinical seroma formation in 24 patients, is described.

Donor-site seroma is a common complication of harvesting myocutaneous flaps, particularly the latissimus dorsi. When the latissimus dorsi flap is used for immediate or delayed breast reconstruction, postoperative drainage from the donor site is often prolonged and copious. In addition, a significant number of patients will often complain about a painful seroma 1 to 2 weeks after hospital discharge from the outpatient clinic. This requires percutaneous needle drainage, with the inherent risks of infection, inadvertent pneumothorax, and possible re-accumulation of the seroma in the ensuing dead space. Conservative neglect of seroma has been advocated,¹ although this fails to address the issue of discomfort and possible dehiscence with implant exposure.²

Methods used to reduce the incidence of seroma have included talc poudrage,³ minimal access harvesting,⁴ fibrin sealant adhesive,⁵ avoidance of electrocautery diathermy,⁶ and quilting of the donor site.⁷ These maneuvers minimize the dead space and prevent the shearing movement thought to be responsible for seroma.

The use of quilting sutures to secure the donor area to the skin flaps reduces the rate of seroma formation to between 0 percent and 9 percent.⁵ However, the method described by Titley and colleagues⁸ involves placing these 3 to 4 cm apart to achieve approximation, often involving up to 30 sutures. Although the original article suggested that this adds 10 to 20 minutes of additional time, in practice this often takes longer.

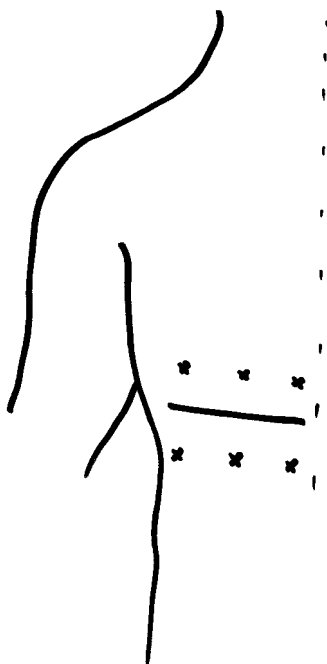


FIG. 1. Incision line with quilting suture placement.

We have adapted the quilting method of Titley and colleagues and modified it with similarly good results. It has been found that very few quilting sutures placed strategically apart are as effective as densely packed multiple quilts. Our method is somewhat simpler, involving a row of three 2-0 polyglactin 910 sutures on either side of the skin flaps (Fig. 1) augmented by a row along the incision line. Instead of the usual dermal sutures, the incision line sutures incorporate part of the underlying subcutaneous tissue as well, thus acting as quilts.

Over the last 2 years, we have used this method in 24 patients with latissimus dorsi breast reconstructions. All the patients have been operated on and followed up by the same surgical team, with no detectable seromas requiring drainage.

Because this technique employs relatively fewer sutures, we feel that it does not add any significant time to the total theater time and would recommend this method to colleagues performing such surgery.

D. G. K. Lam, B.Sc., F.R.C.S.

S. Choudhary, M.S., F.R.C.S.(Ed.)

M. A. M. Cadier, M.A., M.S., F.R.C.S.

Odstock Centre for Burns, Plastic and Maxillo-Facial Surgery
Salisbury District Hospital

Salisbury SP2 8BJ

Wiltshire, U.K.

REFERENCES

1. Reddick, L. P. Seroma after latissimus dorsi myocutaneous flap for breast reconstruction (Letter). *Plast. Reconstr. Surg.* 85: 826, 1990.
2. Slavin, A. S. Seroma after latissimus dorsi myocutaneous flap for breast reconstruction: Reply (Letter). *Plast. Reconstr. Surg.* 85: 826, 1990.
3. Coons, M. S., Folliguet, T. A., Rodriguez, C., et al. Prevention of seroma formation after dissection of musculocutaneous flaps. *Ann. Surg.* 59: 215, 1993.
4. Friedlander, L., and Sundin, J. Minimally invasive harvesting of the latissimus dorsi. *Plast. Reconstr. Surg.* 94: 881, 1994.
5. Kulber, D. A., Baciliou, N., Peters, E. D., et al. The use of fibrin sealant in the prevention of seromas. *Plast. Reconstr. Surg.* 99: 842, 1997.
6. Schwabegger, A., Ninkovic, M., Brenner, E., et al. Seroma as a common donor site morbidity after harvesting the latissimus dorsi flap: Observations on cause and prevention. *Ann. Plast. Surg.* 38: 594, 1997.
7. Freilinger, G., and Frey, M. Funktionelle Muskeltransplantation. In U. Weber, M. Greulich, and M. Sparmann (Eds.), *Orthopaedische Mikrochirurgie*. Stuttgart: Thieme, 1993.
8. Titley, O. G., Spyrou, G. E., and Fatah, M. F. T. Preventing seroma in the latissimus dorsi flap donor site. *Br. J. Plast. Surg.* 50: 106, 1997.

WITCH'S CHIN: A PROGRESSIVE THREE-STEP TECHNIQUE

Sir:

We read with interest Dr. Zide's Discussion of our recent article in the August 1999 issue (*Plast. Reconstr. Surg.* 104: 552, 1999). We appreciate his criticism, because we always seek to improve our knowledge; however, some misunderstandings do need to be clarified. We feel, therefore, that a reply is worthwhile.

Dr. Zide states that our drawing is "very incorrect." If we

compare it with images from an atlas of anatomy or with the picture of a perfect fresh cadaver dissection, then he is right. Generally, a drawing in a scientific article aims to schematically reproduce an anatomical region or a surgical technique, as in our case. However, if the drawing did not *perfectly* represent the true anatomical situation, as Dr. Zide points out about ours, it would be of no particular relevance to a surgeon. If a surgeon has any doubt concerning anatomy, he would obviously look for an appropriate textbook.

We have treated witch's chin in older patients, for whom it represents a very ugly sign of aging and in whom the ptosis of soft tissues is particularly evident. We examine our patients preoperatively, both statically and dynamically, then correct the excess ptotic tissue and evaluate the result in a static position. We deliberately do not treat the submental excess that normally appears when smiling, and this is certainly one of the reasons we had good aesthetic improvements without any functional problem during animation. Dr. Zide shows a young female in Figure 1, which obviously produces some confusion because we always referred exclusively to elderly patients. Furthermore, we note that the chin in Figure 1 has a normal appearance during resting, but a submental excess when smiling. Does this imply that Dr. Zide would treat the submental excess present during smiling in a young female? We very much hope not.

With regard to the first step of the technique (i.e., the de-epithelialized ellipse of skin), Dr. Zide states that the buried dermis works better in the drawing than in real life. We completely disagree with this. The filling effect of the de-epithelialized submental skin is a well-recognized procedure reported by several authors cited in our paper. The exact positioning of the ellipse and the undermining of its anterior and posterior edge lead to very good results, even in the case of a particularly deep submental fold.

Concerning the second step of the technique (i.e. soft-tissue reduction), Dr. Zide says that a "more serious" excision should be performed to correct mental ptosis. It is curious that he judges the amount of tissue to be removed from the schematic illustration, rather than from the result seen in Figure 3. A single illustration could never indicate the exact amount of tissue to be removed. This depends on the degree of deformity and differs considerably between individual patients. An experienced surgeon knows perfectly well how much reduction is required; if any doubt existed, we would certainly not advise a one-step reduction with the risk that it could be excessive, but would instead suggest reducing the tissue step-by-step according to the immediate result, following the intrinsic philosophy of our progressive technique.

Another point also needs to be clarified. Dr. Zide writes that the patients shown in the pictures were not hyperprojected and that the patient in Figure 1 did not need bony reduction. It is a pity that Dr. Zide did not read the legend more carefully. The legend of Figure 1 clearly states that "witch's chin has been corrected by using only the first step of the procedure" (i.e., the ellipse of de-epithelialized skin with no soft-tissue reduction or bone reduction). It is very strange that Dr. Zide misinterpreted this information.

In conclusion, we began reading the Discussion by Dr. Zide with great enthusiasm, honored by his interest because he is a well-known surgeon and, indeed, one who is cited in the references of our article. As we continued to read his comments, we found many misinterpretations and mistakes, rather than objective criticisms, and felt that these were worthy of a reply.

Claudio Bernardi, M.D.
Pier Luigi Amata, M.D.
Stefano Dura, M.D.
Villa Massimo Medical Center
Via G. Severano, 5 00161 Rome, Italy
claber@esgen.it

REPLY

Sir:

The purpose of a Discussion may be to clarify that which was not necessarily well stated or presented in a paper. One of my pet peeves relates to inaccurate schematic or artistic renditions of procedures wherein the operation is dependent on the anatomy. In this procedure, the anatomy was key to the procedure and the schematic detracted from this understanding. In this area, textbooks are classically weak.

For younger patients who exhibit submental excess when smiling, the procedure championed by Feldman (*Plast. Reconstr. Surg.* 90: 207, 1992), which I also use in young patients, provides an excellent way of dealing with dynamic (smiling) ptosis. Therefore, as to the "we very much hope not" statement, I also treat this in the aging patient and the procedure works well.

As for the disagreement regarding the de-epithelialized buried dermis, I could have been clearer. Whereas the classic drawings depict this as a bulky flap, I have rarely been able to get much bulk from a small ellipse, but it does help in filling the fold.

People who read articles on plastic surgery techniques tend to use the diagrams as road maps for trying the procedure. I have noticed that in all courses I have presented or taught. Thus, it is worthwhile to be very clear in the drawings and with any lines put on a patient photo.

With regard to the misinterpretation of the legend on the "bony reduction," Bernardi et al. are correct because the legend does say "only the first step" was used. I was guilty of thinking that bony reduction was involved because the chin prominence looks reduced in the postoperative picture. I have rarely seen a submental wedge excision affecting the chin prominence as was noted here.

I hope this clears up any lack of clarity on my part.

Barry M. Zide, D.M.D., M.D.
New York University Medical Center
420 East 55th Street, Suite 1D
New York, N.Y. 10022

THE "CHEMICAL LEECH" REVISITED

Sir:

I read with interest the May 1999 Journal article on subcutaneous heparin and an ungual window for salvage of replanted digits.¹ A technique very similar to this was first described in 1989 in Melbourne² and has been described elsewhere for digits³ and ears.⁴ The basis of all the described methods is anticoagulant therapy, locally and sometimes systemically, and a wound to allow blood egress. I prefer to use highly concentrated calcium heparin, 5000 IU in 0.2 ml,² which is normally used for subcutaneous deep vein thrombosis prophylaxis. Using a tuberculin syringe, a dose of 500 IU can be administered in 0.02 ml: this means that there are less potential problems with increased tissue tension impairing circulation. I make a stellate wound in the pulp or remove the nail to provide a bleeding area. I now also use very small

gauze packs soaked in dilute heparin-saline (1000 IU in 1 ml) to reduce blood clots forming at the surface and to allow continued bleeding. This technique is widely used in Melbourne to salvage digits and other tissues in which arterial inflow can be established, but not adequate venous drainage.

*Kirstie A. MacGill, F.R.A.C.S.
Department of Plastic and Reconstructive Surgery
Royal Melbourne Hospital
Parkville
Australia 3050*

REFERENCES

1. Iglesias, M., and Butron, P. Local subcutaneous heparin as treatment for venous insufficiency in replanted digits. *Plast. Reconstr. Surg.* 103: 1719, 1999.
2. Barnett, G. R., Taylor, G. I., and Mutimer, K. L. The "chemical leech": Intra-replant subcutaneous heparin as an alternative to venous anastomosis. Report of three cases. *Br. J. Plast. Surg.* 42: 556, 1989.
3. Robinson, C. Artificial leech technique. *Plast. Reconstr. Surg.* 102: 1787, 1998.
4. Nath, R. K., Kraemer, B. A., and Azixxadeh, A. Complete ear replantation without venous anastomosis. *Microsurgery* 18: 282, 1998.

RISK OF TRANSMISSION OF AGENTS ASSOCIATED WITH CREUTZFELDT-JAKOB DISEASE AND BOVINE SPONGIFORM ENCEPHALOPATHY

Sir:

This letter in the April 1999 Journal described a single case report of chin augmentation with a bovine bone substitute.¹ Because of an infection in the augmented area, the bone substitute was removed 10 months later. The nonimplanted bone substitute (Bio-Oss, Geistlich AG, Switzerland) was analyzed for its protein content. Because of misinterpretations of results, the authors claim that Bio-Oss contains proteins and may therefore pose the risk of bovine spongiform encephalopathy transmission. These erroneous statements need to be addressed.

Bone used to make Bio-Oss is assigned to class 4 tissues (no detectable infectivity) by the Scientific Steering Committee of the European Union. Furthermore, review of the production process of Bio-Oss suggests strong chemical inactivation of prions (B. Oesch, unpublished observation).

The authors did not describe the results of histological analysis of the explant. Apart from a lack of evidence that the bone substitute material was the cause of the inflammation, it is a hallmark of prion diseases that no inflammatory reaction occurs upon infection, but rather that the immune system is a mediator for successful infection.² Other explanations for the inflammation seem more likely, such as excessive augmentation of the chin or dense, cortical avascular bone structure in the surgical area compromising the predictability for any bone substitute.

The authors analysed Bio-Oss for its protein content with two methods, polarization microscopy and chemical staining with Coomassie blue. Because of the presence of birefringent structures and a positive chemical staining reaction, they concluded that Bio-Oss does still contain proteins and may pose a risk of bovine spongiform encephalopathy infection.

In native bone, birefringence under polarized light results from both the fine structure of the collagen fibrils and the

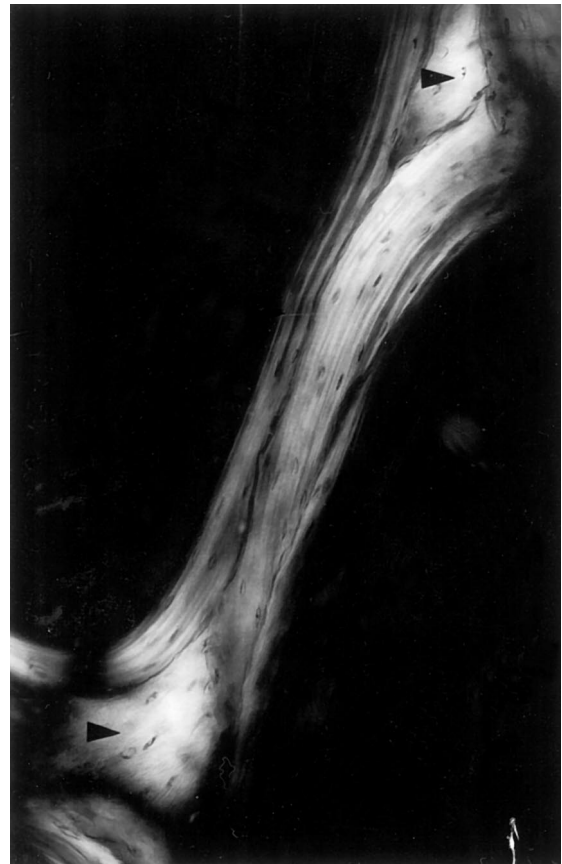


FIG. 1. Native Bio-Oss trabecular in polarized light, unstained ground section, 100 μ m thick, 140:1. Birefringence of the lamellae is caused by parallel arrangement of the apatite crystals. Lamellae oriented parallel to this plane appear as bright areas (arrowheads).

crystallinity of hydroxyapatite (Fig. 1). Birefringence in deproteinized Bio-Oss persists and is solely based on the orientation of the apatite crystals. In contrast, the birefringent behavior of Bio-Oss once again proves that the apatite crystals in it remain oriented as in natural bone.

The method of staining with Coomassie blue is used for quantitative protein measurements in protein solutions under defined experimental conditions. Because the staining is mainly based on the nonspecific binding of the dye anion to certain cationic molecular groups, it is important to previously analyze the specificity of the method for a substrate to be tested. With no controls included in the evaluation, it is impossible to interpret the results. Test results with specific chemical methods demonstrate no detectable protein in Bio-Oss.³

It is important to critically evaluate the risk and safety of products; at the same time, published data on the efficacy of such products should not be concealed. The chemical treatment of Bio-Oss makes it highly unlikely that the material could transmit bovine spongiform encephalopathy. Bio-Oss has consistently been shown to have excellent osteoconductive and biocompatible properties.^{4,5} One should not reject a proven material because of unfounded fears or wrongly interpreted test results. Unsubstantiated opinions such as those expressed by Hönig et al. in a nonreviewed letter to the editor should always be looked at very carefully and critically by the reader.

Niklaus P. Lang, M.S.
 Christoph Hämmerle
 Department of Periodontology and Fixed Prosthodontics
 University of Berne
 Freiburgstrasse 7
 CH-3010, Bern, Switzerland

Bruno Oesch
 Prionics AG
 University of Zurich
 Winterthurerstrasse 190
 CH-8057, Zürich, Switzerland

Robert K. Schenk
 University of Berne
 Department of Oral Surgery
 Freiburgstrasse 7
 CH-3010, Bern, Switzerland

REFERENCES

1. Hönig, J. F., Merten, H. A., and Heinemann, D. E. Risk of transmission of agents associated with Creutzfeldt-Jakob disease and bovine spongiform encephalopathy (Letter). *Plast. Reconstr. Surg.* 103: 1324, 1999.
2. Berg, L. J. Insights into the role of the immune system in prion diseases. *Proc. Natl. Acad. Sci. U. S. A.* 91: 429, 1994.
3. Results on file at Geistlich Pharma AG, Switzerland.
4. Hämmerle, C. H. F., Chiantella, G. C., Karring, T., and Lang, N. P. The effect of a deproteinized bovine bone mineral on bone regeneration around titanium dental implants. *Clin. Oral Impl. Res.* 9: 151, 1998.
5. Valentini, P., and Abensur, D. Maxillary sinus floor

elevation for implant placement with demineralized freeze-dried bone and bovine bone (Bio-Oss): A clinical study of 20 patients. *Int. J. Periodont. Rest. Dent.* 17: 233, 1997.

REPLY

Sir:

The matter-of-factness with which Lang et al. assert that the product Bio-Oss gives no cause for concern is surprising. The authors pointed out in their own investigations¹ that infection may occur after implantation Bio-Oss and that they observed infection in 1 of 100 patients. Thus, it is unreasonable to claim that this product is free of complications. Furthermore, this

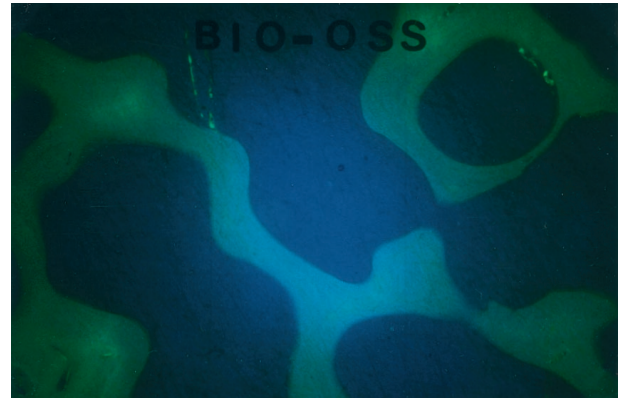


FIG. 1. Fluorescence microscopy of originally packaged Bio-Oss. The product showed fluorescence of its own (violet light $\times 10$).

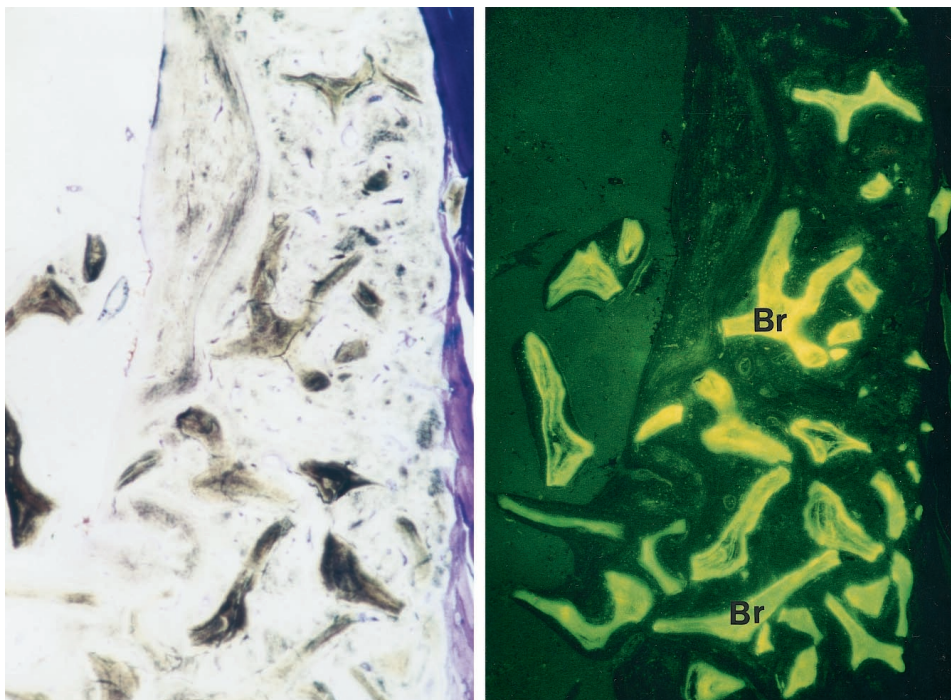


FIG. 2. (Left) Light, microscopic cross section of the mandible's lateral cortical bone 86 weeks after implantation of Bio-Oss in a critical size defect. Note the remnants of Bio-Oss ($\times 5.5$). (Right) Fluorescence microscopy of the mandible's lateral cortical bone. Even 86 weeks after implantation of Bio-Oss in a critical size defect, the Bio-Oss residues still showed fluorescence of their own (blue light $\times 4.5$). Br, Bio-Oss residues.

product is capable of inducing New Bone Formation, as recently demonstrated by an American group.²

In their provocatively titled article, "Ability of Deproteinized Cancellous Bovine Bone (Bio-Oss) to Induce New Bone Formation,"² the authors detected protein-containing substances. Incidentally, this article and its results are known to Lang et al. and to the Geistlich company.¹

Additionally, the issue is not that the German Federal Office for Medicine could not detect any proteins in the given charges of Bio-Oss; on the contrary, the organization stated that they only failed to detect worth-mentioning protein residues in the given charges of Bio-Oss, meaning that the existence of proteins in the given charges could not be excluded safely by the methods they applied.³

If protein-containing substances cannot be excluded safely and if the deproteinized Bio-Oss is able to induce new bone formation, the question arises whether the risk of bovine spongiform encephalopathy transmission can be safely ruled out.

In our own investigation of originally packaged Bio-Oss materials with a charge number known to the German Federal Office for Medicine, we could definitely detect protein-containing substances. We reported our results to the German Federal Office for Pharmaceutical Research and to the German Federal Office for Medicine according to our medical duties, to protect our patients. The originally packaged Bio-Oss products and implants also showed fluorescence of their own (Figs. 1 and 2) possibly caused by feed substances containing antibiotics the animals had ingested and integrated in their bones or perhaps because of the actual Bio-Oss production process providing a possible allergeneous potency for patients after implantation.

It is the choice of Lang et al. not to act with regard to medical care. In contrast, we make it our duty to point out risks and side effects.

We and other surgeons renounce the further application of Bio-Oss until it is unequivocally determined by the German Federal Office for Medicine whether the product is absolutely safe and totally free of bovine material.

J. F. Hönig, M.D., Ph.D.

H. A. Merten, M.D., Ph.D.

Department of Craniofacial and Plastic Surgery
University Hospital and Medical School of Goettingen
Robert-Koch-Street 40
37075 Goettingen
Germany

REFERENCES

1. Lang, N., Schenk, R. K., et al. Landgericht Goettingen, Geschäfts-Nr.: 40 254/99; 11. August 1999.
2. Schwartz, Z., Weesner, T., van Dijk, S., et al. Ability of deproteinized cancellous bovine bone (Bio-Oss) to induce new bone formation. *J. Periodontol.* (in press).
3. Bundesinstitut für Arzneimittel und Medizinprodukte, Letter No. 922-4212-DT-5672/99.

A PEDICLE-LENGTHENING TECHNIQUE FOR ABDUCTOR HALLUCIS MUSCLE FLAP

Sir:

The abductor hallucis muscle can be used to cover defects of the heel and the medial malleolus as a turn-over flap or as an island flap based on a single perforator. If the flap is designed to fill a cavity in the calcaneus or to cover defects

over the distal Achilles tendon, additional pedicle length is necessary. In addition, the distal tendinous part of this muscle is usually excised to obtain a muscle belly flap. This shortens the length of the flap and makes the arc of rotation quite limited. The arc of rotation can be gained by dissecting an island-pedicle muscle flap based on the medial plantar artery and by mobilizing the tibialis posterior artery as far proximally as the medial malleolus. This procedure moves the pivot proximally. However, it adds a degree of complexity and risk. The use of the medial plantar artery does not seem very significant when balanced against the advantages of this procedure.

One case is illustrated in Figure 1. A 20-year-old man sustained a closed, comminuted calcaneus fracture when he was hit by a car 4 years previously. The patient had a draining

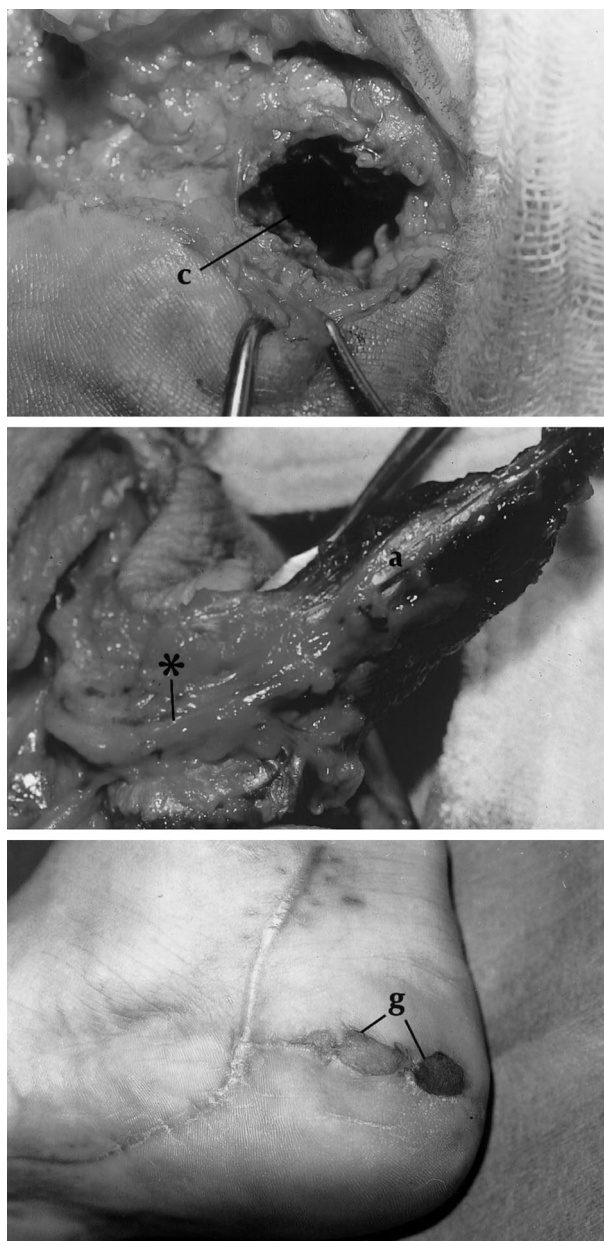


FIG. 1. (Above) Osteomyelitic cavity in the calcaneus (c). (Center) An abductor hallucis muscle flap (a) based on the medial plantar artery (star) was raised. (Below) The wound healed with no problems. G, graft.

sinus on the medial aspect of the right foot. Several curettings of the cavity were performed unsuccessfully. During the operation, a deep osteomyelitic cavity in the calcaneus was noted. The wound and cavity were debrided. An abductor hallucis muscle flap based on the medial plantar artery was planned for filling the osteomyelitic lesion in the calcaneus. The muscle was separated from both its origin and its insertion, and tendinous part was excised. The muscle was mobilized by dividing the distal end of the medial plantar artery, then converted to a true island-pedicled flap. The tibialis posterior artery was mobilized as far proximally as the medial malleolus, thus preserving the lateral plantar artery. Intra-calcaneal cavity was filled with muscle, which was covered with a small, full-thickness skin graft. The muscle comfortably filled the defect. The size of the muscle belly was adequate for the size of the defect. The skin graft took well, with a nice contour. The patient has maintained a closed wound for 1 year.

This technique increases the range and application of the abductor hallucis muscle flap. We are not aware of its clinical use, although Schefflan and Nahai discussed theoretical knowledge of a similar technique.

Ahmet Karacalar, M.D.
Department of Plastic and Reconstructive Surgery
Division of Hand Surgery
Medical Faculty of Uludağ University
Bursa, Turkey

REFERENCE

1. Schefflan, M., and Nahai, F. Foot. In S. J. Mathes and F. Nahai (Eds.), *Clinical Applications for Muscle and Musculocutaneous Flaps*. St. Louis: Mosby, 1982. Pp. 594–609.

WHAT'S WRONG WITH DERMABOND?

Sir:

I am one of those who believe the routine excision of traumatic wounds to be unnecessary. I don't know of any controlled studies that would support this traditional but unproven practice. "Always debride the traumatic wound" is not, as far as I could determine, included by Millard¹ as one of the principles of plastic surgery.

Nonetheless, I believe it is important to explore, clean, and irrigate traumatic wounds, which does generally require local anesthesia, so I would agree that the company's emphasis is misdirected.

Personally, I find Dermabond most useful for elective breast and abdominal surgery with subcuticular closure. By applying Dermabond, any protective dressings can be removed in a day or two and the patient can briefly shower over the operated area, greatly adding to their comfort and sense of recovery.

Richard Solmer, M.D.
17742 Beach Boulevard, Suite 300
Huntington Beach, Calif. 92647

REFERENCE

1. Millard, D. R. *Principles of Plastic Surgery*. Boston: Little, Brown, 1986.

BREAST AUGMENTATION: COMPRESSION—A VERY IMPORTANT FACTOR IN PREVENTING CAPSULAR CONTRACTURE

Sir:

With regard to Dr. Boyd R. Burkhardt's Discussion in the November 1999 issue of the Journal (*Plast. Reconstr. Surg.* 104: 529, 1999), the reader must know that the eight postoperative wound infections were not periprosthetic. If we have a periprosthetic infection, we remove the implant. Otherwise it will not heal, even with long-term antibiotics.

We never tried or pretended to prove scientifically that compression prevents capsular contracture. However, I am sure we agree that compression of the implant inevitably stretches the slow-contracting capsule. Can anyone think of a better way of antagonizing a contracture than by stretching it?

The purpose of our publication was to share with the readers that, in our large series, by using early postoperative compression, none of our patients required surgery for a capsular contraction.

I certainly appreciate and humbly accept the respect and commendation gracefully addressed by Dr. Burkhardt, and I agree that my team deserves a medal for their phenomenal and efficient work.

One thing is very obvious—we have not missed our mark by using early compression in our breast augmentations. We hope our experience can help our colleagues.

André Camirand, M.D.
Clinique Chirurgie Esthétique
12245 rue Grenet, 112B
Montreal, Quebec
Canada H4J 2J6

MAINTENANCE OF NIPPLE PROJECTION USING AURICULAR CARTILAGE

Sir:

With regard to the article and Discussions in the August 1999 Journal issue,^{1–3} there are several methods of nipple reconstruction that depend mainly on morphology of the contralateral nipple and preference of the reconstructing surgeon after consultation with the patient. Maintenance of nipple projection can be a problem that often necessitates production of an initially oversized nipple to allow for subsequent shrinkage. When nipple sharing is not an option, we frequently use the C-V flap, a modification of the skate flap that is also favored by Dr. Bostwick.³ The nipple flap is tattooed before raising. The areola is then tattooed after the nipple has been formed and the donor site closed with subcutaneous Monocryl. Nipple projection is maintained by incorporating a small piece of auricular cartilage inside the flap. The cartilage used is the posterior extension of the sharp fold in the upper conchal fossa palpable in the postauricular sulcus. The presence of the cartilage in maintaining projection means that the initial flap does not have to be so oversized, which in turn makes the donor site easier to close. Nipple projection has been maintained in the 2 years that we have been using this technique, and we have not encountered any problems associated with it. The use of auricular cartilage was first described by Brent and Bostwick.⁴ Tanabe⁵ later modified the method using rolled auricular cartilage (1 × 2 cm) wrapped inside a bilobed flap and surrounded by a skin graft. We believe that our technique is simpler and quicker, requiring a smaller amount of inconspicuous cartilage.

N. Collis, B.Sc., F.R.C.S.(Ed.)
A. Garrido, L.M.S., F.R.C.S.(Ed.)
Le Roux Fourie, F.R.C.(S.A.)(Plast.), F.R.C.S.
Department of Plastic Surgery
Pinderfields and Pontefract NHS Trust
Aberford Road, Wakefield
West Yorkshire WF1 4DG, England
United Kingdom

REFERENCES

1. Kroll, S. S. Nipple reconstruction with the double-opposing tab flap. *Plast. Reconstr. Surg.* 104: 511, 1999.
2. Little, J. W. Reconstruction with the double-opposing tab flap (Discussion). *Plast. Reconstr. Surg.* 104: 515, 1999.
3. Bostwick, J. Reconstruction with the double-opposing tab flap (Discussion). *Plast. Reconstr. Surg.* 104: 516, 1999.
4. Brent, B., and Bostwick, J. Nipple-areola reconstruction with auricular tissues. *Plast. Reconstr. Surg.* 60: 353, 1977.
5. Tanabe, H. Y., Tai, Y., Kiyokawa, K., and Yamauchi, T. Nipple-areola reconstruction with a dermal fat flap and rolled auricular cartilage. *Plast. Reconstr. Surg.* 100: 431, 1997.

NIPPLE RECONSTRUCTION AND MASTECTOMY SCARS

Sir:

With regard to the article and discussions in the August 1999 Journal issue,¹⁻³ the site of proposed nipple reconstruction often lies along the path of a mastectomy scar. This may deter some surgeons from performing local flap reconstructions for fear of partial or total nipple necrosis. In our unit, we have performed sixty-eight "mushroom" nipple-areola reconstructions (in 60 patients) in our unit between 1989 and 1998. All were the last stage of delayed breast reconstructions by tissue expansion, sixty-six following mastectomy and two following reconstruction after childhood burns. The details of the technique have previously been reported², but briefly involves a gathered 3 cm diameter circular flap pedicled on its central 1 cm. The 1 cm wide donor ring is filled with a full-thickness skin graft from the groin to recreate the areola, which is later tattooed. The patients notes were reviewed. There was no loss of nipple reconstructions in our series. The presence of mature scar tissue in the skin used to construct nipples does not appear to be detrimental to the use of this particular method of nipple reconstruction.

N. Collis, B.Sc., F.R.C.S.(Ed.)
M. T. Laloo, M.B.Ch.B.
D. T. Sharpe, O.B.E., M.A., F.R.C.S.
Department of Plastic Surgery
Bradford Royal Infirmary
Duckworth Lane, Bradford
West Yorkshire BD9 6RJ, England
United Kingdom

REFERENCES

1. Kroll, S. S. Nipple reconstruction with the double-opposing tab flap. *Plast. Reconstr. Surg.* 104: 511, 1999.
2. Little, J. W. Reconstruction with the double-opposing tab flap (Discussion). *Plast. Reconstr. Surg.* 104: 515, 1999.

3. Bostwick, J. Reconstruction with the double-opposing tab flap (Discussion). *Plast. Reconstr. Surg.* 104: 516, 1999.
4. Hobson, M. I., Williams, N., and Sharpe, D. T. The "mushroom" nipple-areola reconstruction: A patient review. *Ann. Plast. Surg.* 37: 453, 1996.

AN INEXPENSIVE AND EFFICIENT METHOD TO KEEP THE DIFFICULT ANASTOMOTIC SITE CLEAR IN MICROVASCULAR SURGERY

Sir:

Performing microvascular anastomoses in very deep locations such as the thigh or popliteal area can be tedious and difficult, particularly when edematous fluids and blood continuously flood the area. Intermittent suctioning is usually required, which disturbs the workflow. We have used a simple technique to successfully avoid this problem.

A standard suction drain (which can be used later for its original purpose) is connected to a suction cannula, allowing for continuous aspiration (Fig. 1). The drain is placed at the deepest point of the anastomotic site, then covered by a piece

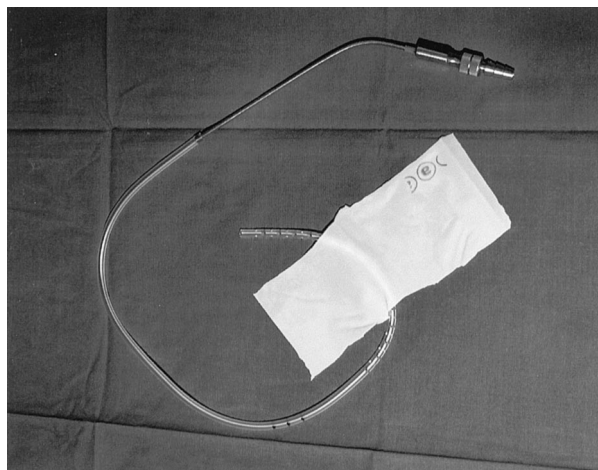


FIG. 1. A suction drain connected to the suction device. The area of perforations is covered by a piece of rubber glove.

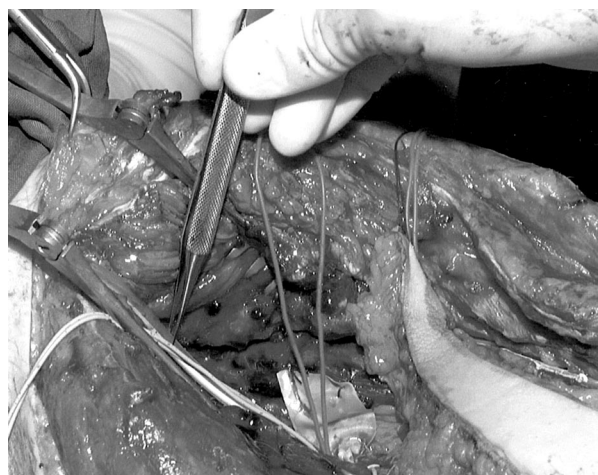


FIG. 2. Suction drain placed at the anastomotic site with a piece of rubber located beneath the vessels.

of rubber glove that passes under the vessels to be anastomosed (Figs. 1 and 2). This assembly guarantees permanent clearance of fluids without the risk of trapping tissue or even microvessels in the suction drain during performance of the anastomosis. Abundant irrigation fluid is washed away in a gentle fashion.

Peter M. Vogt, M.D., Ph.D.

Frank W. Peter, M.D., Ph.D.

Heinz-Herbert Homann, M.D.

Thomas Muehlberger, M.D.

Hans-Ulrich Steinau, M.D., Ph.D.

Department of Plastic Surgery, Hand Center and Burn Center

BG-Kliniken Bergmannsheil

Ruhr-University

Bürkle-de-la-Camp-Platz 1

D-44789 Bochum

Germany

A "PAINFUL" OLIVE

Sir:

As a clinical sign, a mass urges to be characterized as one more piece of the semiological puzzle that leads to the diagnosis. Most of the time it is the main reason for consultation, at which time it is classically characterized by its size, location, time of evolution, growth, consistency, adherence to the superficial or deep planes, and associated signs or symptoms such as pain, itching, or bleeding.

Between 1988 and 1997, in the course of a retrospective, departmental study on hand tumors, we verified that it is standard practice for a doctor to register the size of a mass not by the international system of measure but by comparison of the mass with well-known models.

Motivated by the frequency with which this practice occurred, we began a detailed analysis of the comparison models used. We analyzed 30 clinical cases with regard to the model used, the clinical or anatomic-pathologic diagnosis to which it corresponded, and its dimensions in the international system of measure when the anatomic-pathologic examination of the operative piece was requested.

Table I summarizes the comparison models used. Table II compares the exact expression written by the doctor with the clinical or anatomic-pathologic diagnosis to which the expression corresponds. Table III compares the real size of some of the models used with the dimensions of the lesion as mentioned in the description from the anatomic-pathologic examination.

It is interesting to examine how precision exists in the

TABLE I
Models Used and Their Frequency

Model	Frequency
Olive	7
Pea	6
Corn	6
Hazelnut	3
Rice	2
Pigeon's egg	2
Chickpea	1
Chestnut	1
Cherry	1
Tangerine	1
TOTAL	30

TABLE II
Expressions Used and Their Corresponding Diagnoses

Expression	Diagnosis
"Olive"	Giant cell tumor tendon sheath
"Olive"	Epidermoid inclusion cyst
"Olive"	Epidermoid inclusion cyst
"Elvas olive"	Schwannoma
"Black olive"	Giant cell tumor tendon sheath
"Black olive"	Ganglion cyst
"Painful olive"	Ganglion cyst
"Pea"	Epidermoid inclusion cyst
"Pea"	Epidermoid inclusion cyst
"Pea"	Ganglion cyst
"Little pea"	Ganglion cyst
"Little pea"	Ectopic ungual matrix
"Grain of pea"	Foreign-body granuloma
"Grain of corn"	Foreign-body granuloma
"Grain of corn"	Seborrhic wart
"Grain of corn"	Blue nevus
"Grain of corn"	Ganglion cyst
"Grain of corn"	Ganglion cyst
"Grain of corn"	Ganglion cyst
"Grain of corn"	Ganglion cyst
"Hazelnut"	Ganglion cyst
"Hazelnut"	Ganglion cyst
"Hazelnut"	Ganglion cyst
"Grain of rice"	Tenosynovial chondrometaplasia
"Grain of rice"	Ganglion cyst
"Pigeon's egg"	Schwannoma
"Pigeon's egg"	Ganglion cyst
"Chickpea"	Epidermoid inclusion cyst
"Big cherry"	Vascular leiomyoma
"Chestnut"	Giant cell tumor tendon sheath
"Tangerine"	Hemangiopericytoma

clinical eye, but even more so to guess how this analysis could contribute to a future study on the imagery of doctors considering that 100 percent of the models used here were of alimentary origin. More than any other class of items, the alimentary figure seemed strongly present in the imagery our colleagues used for professional activity.

The reason why this imagery occurred could well have been because the consultation period happened just before or soon after lunch or because food was to be profiled as a compensation for professional stress, but that is a matter to be studied by psychologists. The fact is that we did not find a shirt button, small coin, or golf ball amongst the models used. Could this be because doctors only pay for their expenses with electronic cards and have forgotten the touch of

TABLE III
Model Size versus Mass Dimension

Model	Size (mm)	Diagnosis	Dimension (mm)
Olive	18	Giant cell tumor tendon sheath	16 × 10
Olive	18	Epidermoid inclusion cyst	16
Elvas olive	20	Schwannoma	15 × 7 × 3
Pea	7	Epidermoid inclusion cyst	6 × 3
Grain of corn	11	Foreign-body granuloma	14
Grain of rice	7	Tenosynovial chondrometaplasia	5
Pigeon's egg	35	Schwannoma	34 × 28
Chickpea	12	Epidermoid inclusion cyst	12 × 8
Big cherry	20	Vascular leiomyoma	20 × 13 × 10
Chestnut	30	Hemangiopericytoma	30

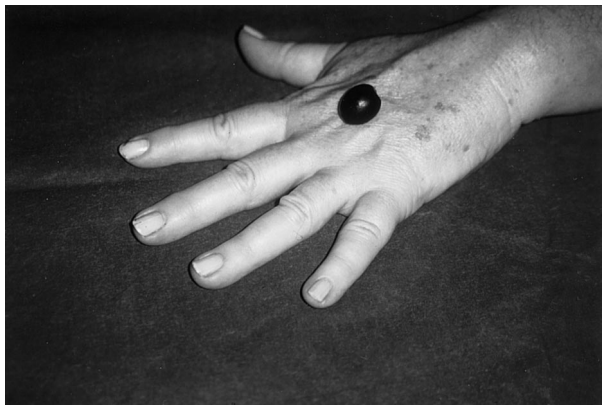

FIG. 1. A "painful" olive.

a dime, emphasizing a sign of modern times? Or do doctors not practice sports very often, emphasizing the sad reality of a lack of time for themselves?

The imagery of the doctors proved versatile. Epidermoid inclusion cysts, for example, were mostly compared to an olive, a pea, or a chickpea. Ganglion cysts were compared to a little pea, a grain of corn, a hazelnut, or a grain of rice, just to name a few. Giant cell tumors were compared to an olive or, when the doctor tried to be more precise, to a black olive or a chestnut.

Interestingly, in a reverse analysis an olive could represent several pathologic entities, including a giant cell tumor's tendon sheath, an epidermoid inclusion cyst, and a schwannoma. A pea could correspond to an epidermoid inclusion cyst, a ganglion cyst, or a foreign-body granuloma. A grain of corn could stand for a seborrheic wart, a blue nevus, or a ganglion cyst.

Humorously, there was a patient file in which the identification between mass and model settled in the doctor's mind in such a way that he named the model after a symptom of the lesion, comparing a symptomatic ganglion cyst with a "painful" olive. Also of interest is the fact that the rarer the diagnosis, the more exclusive the model. Only an hemangiopericytoma was compared with a tangerine, and only a vascular leiomyoma was compared with a big cherry; in these two cases, the hypothesis might be that the mass coloration played a role in the type of fruit chosen, as was certainly the case with the tenosynovial chondrometaplasia choice of a grain of rice. Ultimately, we leave you with two final questions. Would the pigeon's egg represent, in the precise moment of its writing, a desire to fly away from the consultation room? And would the Elvas olive, originating from a city in the south of Portugal, represent a desire for escape to a deserved weekend destination?

Whatever the reasons, we believe that classifying the size of a mass through comparison with an alimentary or other item can be a valid method, certainly better than the absence of any reference to size at all.

João Guimarães, M.D.

Rita Vieira, M.D.

Marques Moura, M.D.

Antonello Ferraro, M.D.

*Plastic, Reconstructive and Aesthetic Surgery Unit
Hospital da Prelada*

Rua de Sarmento Beires, 153

4200-Porto

Portugal

POSTOPERATIVE MONITORING OF MICROVASCULAR TISSUE TRANSPLANTS WITH AN IMPLANTABLE DOPPLER PROBE

Sir:

Recent advances in microsurgical technique over the past 25 years have led to a steady rise in the success rate of microvascular free-flap practice. Khouri et al., in a multicenter, prospective evaluation of free-flap surgery in 1998, reported an overall failure rate of 4.1 percent.¹ However, resalvage rates after vascular thrombosis or insufficiency have not increased to a proportional degree. Several large studies within the last 5 years continue to report resalvage rates below 50 percent after postoperative ischemic events.^{2,3} In the past, surgeons have used a number of options for monitoring flaps and replants; some of which include clinical observation, temperature, isotope clearance, transcutaneous/laser Dopplers, transcutaneous oxygen tension, reflection plethysmography, dermofluorometry, tissue pH, electromagnetic flowmetry, flap hematocrit, interstitial fluid pressure, and magnetic resonance imaging. All have been met with variable degrees of success.⁴⁻⁸

In 1988, Swartz introduced an implantable Doppler probe as a promising monitor of blood flow through microvascular flaps, especially when placed around the anastomosed vein.⁹ Subsequent studies indicated similar improvements in detection of ischemia and resalvage rates, particularly when evaluating buried flaps.¹⁰ In an April 1998 Journal article by Kind et al, a modified technique of the implantable Doppler ultrasonic probe previously described by Swartz was evaluated in 147 consecutive flap procedures. The authors described 20 instances of thrombosis or spasm detected in 16 of the patients, with a 100 percent salvage rate of ischemic flaps. There were 4 false positives and no false negatives.¹¹

We have used the implantable Doppler probe (Cook-Swartz Doppler Probe, Cook Incorporated, Bloomington, Ind.) in our free-tissue transplantation practice and report two cases of potential interest.

The first case involves a 15-year-old man who presented with a mass in the right side of his mouth consistent with a fibrocystic variant of myeloblastoma. The patient underwent resection of the right hemimandible and subsequent mandibular reconstruction with a fibular free flap. Microvascular, end-to-end anastomosis of the peroneal artery to the recipient facial artery was accomplished with 9-0 and 10-0 nylon sutures. Patency of the anastomoses were confirmed by Dopplerable signals and a positive "fill test." Following completion of the anastomosis, an implantable Doppler probe was placed distal to the anastomotic vein for postoperative monitoring.

At approximately 20 hours postoperatively, no signal from the implantable probe was appreciated by the intensive care unit staff. The patient was immediately reevaluated in the operating room, with a presumptive diagnosis of venous thrombosis at the flap site. Upon exploration, both vessels were noted to be patent; however, the closure of the platysma was tight over the vein, which resulted in veno occlusion. Upon closure, the platysma was left open in an effort to minimize the local edema and the pressure on both arterial and venous anastomoses. The patient's course from that point was uncomplicated with continued viability of the original fibular flap.

The second case involves a 66-year-old man with a diagnosis of squamous cell carcinoma of the tongue. The patient underwent floor of mouth and tongue resection, neck dissection, and radial forearm free-tissue transfer reconstruction with a tracheostomy and split-thickness skin graft coverage of

the forearm. Anastomosis of artery and vein was performed as discussed above, with implantation of the Cook-Swartz Doppler Probe distal to the venous anastomotic site. At 10 hours postoperatively, a diminished signal was reported from the implantable probe. Examination at the site demonstrated a healthy, pink flap with no appearance of congestion. Furthermore, a strong arterial signal over the flap was elicited. Based on clinical observation of the site, the decision was made not to take the patient to the operating room for surgical re-exploration, despite the absent Doppler signal. It was later revealed that the machine's battery power was low, unbeknownst to the staff and operating team. The "low battery" indicator had not illuminated. After changing the monitor's battery, the signal was restored. The patient's further hospital course was unremarkable, and he was discharged without complication.

Overall, we are encouraged by the success enjoyed thus far using the Cook-Swartz implantable probe to detect anastomotic problems and external compression. We report a false positive result with the probe in an effort to stress the importance of clinical evaluation when making the decision for re-exploration. We look forward to continued developments in the Cook-Swartz Doppler Probe product and to improvements in operative placement and technique as a means of achieving optimal accuracy in the detection of free-flap failure.

Jeffrey B. Wise, B.A.

Mia Talmor, M.D.

Lloyd A. Hoffman, M.D.

Lloyd B. Gayle, M.D.

Department of Surgery, Division of Plastic Surgery

The New York-Presbyterian Hospital-Cornell Medical Center

New York, N.Y. 10021

REFERENCES

1. Khouri, R. K., Cooley, B. C., Kunselman, A. R., et al. A prospective study of microvascular free-flap surgery and outcome. *Plast. Reconstr. Surg.* 102: 11, 1998.
2. Kroll, S. S., Schustermann, M. A., Reece, G. P., et al. Timing of pedicle thrombosis and flap loss after free-tissue transfer. *Plast. Reconstr. Surg.* 98: 1230, 1996.
3. Schustermann, M. A., Miller, M. J., Reece, G. P., Kroll, S. S., Marchi, M., and Goepfert, H. A single center's experience with 308 free flaps for repair of head and neck cancer defects. *Plast. Reconstr. Surg.* 93: 472, 1994.
4. Aoyagi, F., Fujino, T., and Ohshiro, T. Detection of small vessels for microsurgery by a Doppler flowmeter. *Plast. Reconstr. Surg.* 55: 372, 1975.
5. Furnas, H., and Rosen, J. M. Monitoring in microvascular surgery. *Ann. Plast. Surg.* 26: 265, 1991.
6. Grotting, J. C. Free flap monitoring: A review of current practice (Commentary). *Microsurgery* 16: 727, 1995.
7. Hirigoyen, M. B., Urken, M. L., and Weinberg, H. Free flap monitoring: A review of current practice. *Microsurgery* 16: 723, 1995.
8. Machen, H. G., Mailaender, P., Rieck, B., and Berger, A. Techniques of postoperative blood flow monitoring after free-tissue transfer: An overview. *Microsurgery* 15: 778, 1994.
9. Swartz, W. M., Jones, N. F., Cherup, L., and Klein, A. Direct monitoring of microvascular anastomoses with the 20-MHz ultrasonic Doppler probe: An experimental and clinical study. *Plast. Reconstr. Surg.* 81: 149, 1988.
10. Swartz, W. M., Izquierdo, R., and Miller, M. J. Implantable venous Doppler microvascular monitoring: Laboratory investigation and clinical results. *Plast. Reconstr. Surg.* 93: 152, 1994.
11. Kind, M. K., Buntic, R. F., Buncke, G. M., Cooper, T. M., Siko, P. P., and Buncke, H. J. The effect of an implantable Doppler probe on the salvage of microvascular tissue transplants. *Plast. Reconstr. Surg.* 101: 1268, 1998.