

# Injectable Treatments for the Aging Face

Jeffrey B. Wise, M.D.<sup>1</sup> and Timothy Greco, M.D., F.A.C.S.<sup>1,2</sup>

## ABSTRACT

The use of injectable agents, specifically soft tissue fillers and botulinum toxin type A, has risen dramatically over recent years, due to the increased demand for minimally invasive techniques. In fact, today they represent the most commonly performed cosmetic procedures in the United States, with botulinum type A injections topping the list. In the treatment of the aging face, these agents, when used individually or in combination, can effectively decrease rhytids and restore lost volume. The result is a fuller, smoother, more youthful appearance. This article provides an overview of botulinum type A (Botox Cosmetic; Allergan, Inc., Irvine, CA) and the two injectable fillers most commonly used in our practice, namely hyaluronic acid (Restalyne; Medicis Aesthetics, Inc., Scottsdale, AZ) and human-derived collagen (Cosmoderm and Cosmoplast; Inamed Aesthetics, Inc., Santa Barbara, CA). Although we commonly use autologous fat as an injectable filler for facial-volume augmentation, its discussion is beyond the scope of this article. Conceptually, the aging face can be divided into upper, middle, and lower thirds. Using this framework, we will discuss our treatment strategies for addressing each facial region. General principles, preinjection evaluation, and specific approaches and techniques for each anatomic region will be discussed, with particular emphasis on the benefit of using dermal fillers in conjunction with botulinum toxin type A to achieve optimal aesthetic results for facial rejuvenation.

**KEYWORDS:** Injectables, fillers, botulinum toxin, aging face, aesthetic surgery, hyaluronic acid, collagen

According to the American Society for Aesthetic Plastic Surgery, of the nearly 11.5 million cosmetic procedures performed in the United States in 2005, 9.3 million were nonsurgical. Botulinum type A injections accounted for 3.3 million procedures in 2005, and hyaluronic acid administration numbered 1.2 million procedures. Since 1997, nonsurgical procedures have increased by 726%. In 2005, injectable treatments for the aging face were performed 25 times more frequently than rhinoplasty surgery and 33 times more frequently than facelift surgery.<sup>1</sup>

As the demand for minimally invasive cosmetic procedures continues to rise, facial plastic and reconstructive surgeons must be able to offer patients a wide

range of treatment options for the management of the aging face. Interventions may include surgical procedures, ablative (i.e., CO<sub>2</sub>, erbium, YAG lasers) and nonablative (i.e., intense pulse light) therapies, topical treatments, or injectable products, including neurotoxins such as botulinum type A and volume-enhancing fillers. Injectables offer the advantage of decreased postprocedure recovery. In addition, they are ideally suited for those patients who are not physically, emotionally, or financially prepared to undergo a more extensive surgical procedure, or for those patients who seek a more conservative improvement to their appearance. Clearly, in some cases, the use of injectables is incompatible with the aesthetic goals of the patient. Therefore, a

<sup>1</sup>Division of Facial Plastic and Reconstructive Surgery, Department of Otorhinolaryngology—Head and Neck Surgery, University of Pennsylvania School of Medicine, Philadelphia, Pennsylvania;

<sup>2</sup>Eastern Cosmetic Surgery Institute, Bala Cynwyd, Pennsylvania.  
Address for correspondence and reprint requests: Jeffrey B. Wise, M.D., 145 East 27th Street, #8C, New York, NY 10016.

Modern Surgery of the Aging Face; Guest Editors, Adam T. Ross, M.D., Jeffrey B. Wise, M.D.

Facial Plast Surg 2006;22:140–146. Copyright © 2006 by Thieme Medical Publishers, Inc., 333 Seventh Avenue, New York, NY 10001, USA. Tel: +1(212) 584-4662.  
DOI 10.1055/s-2006-947720. ISSN 0736-6825.

comprehensive understanding on the part of the surgeon, along with proper management of patient expectations, is critical to successful outcomes.

Herein, an overview of botulinum toxin type A, along with the volume-enhancing fillers most commonly used in our practice—hyaluronic acid and human-derived collagen—will be provided. Additionally, our treatment strategies for each subunit of the face using injectables will be described, with particular emphasis placed on the synergistic effect of botulinum toxin and fillers in the achievement of optimal aesthetic outcomes.

## OVERVIEW OF BOTULINUM TOXIN TYPE A

The use of botulinum toxin type A as a therapeutic agent dates back almost 30 years. In 1980, Scott first published its use in the treatment of strabismus and later blepharospasm.<sup>2</sup> Since that time, its use has been expanded to include the treatment of focal dystonias, spastic disorders, gastrointestinal sphincter spasms, migraine and tension headaches, hyperhidrosis, tremors, and temporomandibular disorders.<sup>3</sup> On April 15, 2002, the U.S. Food and Drug Administration (FDA) approved botulinum toxin type A for the temporary improvement in the appearance of moderate to severe glabellar lines, signifying the FDA's first cosmetic indication. Today, several "off-label" cosmetic indications are safely performed on other sites of the face, including horizontal forehead lines, "crow's feet," "bunny lines," the perioral area, the dimpled chin, and platysmal bands.<sup>4</sup>

Botulinum toxin type A decreases facial lines and wrinkles at sites of skin pleating caused by hyperfunctioning mimetic muscles. The bacteria, *Clostridium botulinum*, produces seven distinct neurotoxins, one of which is the "A" strain. The structure of the molecule is a dichain linked with disulfide bond. The light chain, a zinc-dependent metalloprotease, cleaves SNAP-25, a protein that is ultimately responsible for exocytosis of the presynaptic, acetylcholine-containing vesicle. The end result is muscular weakness or flaccid paralysis. Clinically, the weakening effects of botulinum toxin type A last ~3 to 4 months, but reports have indicated clinical efficacy for up to 6 months, depending on patient and injection site.<sup>4,5</sup>

The "unit" as a measure of botulinum toxin type A has been standardized by *in vitro* mouse assays. Specifically, 1 U of botulinum toxin type A corresponds to the amount of toxin required to kill 50% of a group of 18- to 20-g female Swiss-Webster mice.<sup>5</sup> In its clinical application in humans, botulinum toxin type A has proven to be extremely safe. Extrapolating the data from mouse experimentation, Meyer and Eddie estimated that a 104-kg adult male would sustain a lethal dose of botulinum toxin type A at amounts exceeding 3500 U, a dose that far surpasses any dosing regimen in the cosmetic treatment of the aging face.<sup>6</sup> Exemptions include pa-

tients with peripheral motor neuropathic diseases or neuromuscular functional disorders such as Eaton-Lambert syndrome and myasthenia gravis. Similarly, botulinum toxin type A is contraindicated in pregnant patients and those who are lactating, although unintentional administration has not resulted in birth defects or pregnancy issues. Finally, caution should be taken when injecting botulinum toxin type A to those taking aminoglycoside antibiotics or other agents that interfere with neuromuscular transmission.<sup>7</sup>

## OVERVIEW OF INJECTABLE FILLERS

Nonpermanent injectable biofillers can be effective tools in the armamentarium of the facial plastic surgeon for the correction of subcutaneous volume loss, one of the hallmarks of facial aging. The search for the "perfect filler" is ongoing. However, the ideal agent should possess the following: biocompatibility (i.e., does not require sensitivity testing, will not promote an antigenic host response), ease and reproducibility of injection, safety (i.e., noncarcinogenic), minimal donor site morbidity, durability but not necessarily permanence, absence of site migration, and a natural feel relative to the native tissue.<sup>8</sup>

Although free fat grafting was described in the 1890s, the modern era of soft tissue augmentation began in the late 1970s with the development of bovine collagen injection.<sup>9</sup> Since that time, numerous biofillers have been developed for soft tissue augmentation—human-derived collagen, autologous fat, expanded polytetrafluoroethylene, silicone, hyaluronic acid, micronized acellular dermal matrix, and calcium hydroxylapatite, to name a few. Many of these agents have limitations to their use, such as the need for sensitivity testing, host inflammatory reactions, lack of durability, and tissue contraction.<sup>10</sup>

Currently, there are dozens of agents that have been FDA-approved for use as dermal fillers. The following sections describe two biofillers that are commonly utilized in our practice for soft tissue augmentation of the aging face—hyaluronic acid and human-derived collagen. We believe that these agents are generally well tolerated by patients and allow for the most predictable and reproducible outcomes in the treatment of the aging face.

## HYALURONIC ACID

Like many aesthetic materials, early uses of hyaluronic acid involved noncosmetic indications. For example, since the 1970s, ophthalmologists have injected hyaluronic acid into globes for volume maintenance during intraocular surgery.<sup>11</sup> The first investigations into hyaluronic acid as a dermal filler were undertaken by Endre Balazs in 1989. He determined that although

hyaluronic acid was biocompatible and nonimmunogenic, in its pure form, its half-life ranged from only 12 hours to a few days.<sup>12</sup> Modern hyaluronic acid formulations have addressed this issue. By stabilizing the polymer through a cross-linking process, its durability as a dermal filler has been dramatically improved.

Hyaluronic acid is a glycosaminoglycan biopolymer that serves as a vital component to the extracellular matrix in adult animal tissue. It has been estimated that a human body weighing 60 kg contains ~12 g of naturally occurring hyaluronic acid.<sup>13</sup> Its molecular composition makes it a highly hydrophilic, drawing in water to its matrix. Additionally, hyaluronic acid's propensity to form extended conformations allows it to occupy large volumes relative to its mass and to withstand significant compressive forces. All of the above properties make it an excellent dermal filler.<sup>12</sup>

Four hyaluronic acid formulations have been approved by the FDA for use in the treatment of mid to deep dermal implantation for the correction of moderate to severe facial wrinkles and folds: Restylane (Medicis Aesthetics, Inc., Scottsdale, AZ), Captique, Hylaform, and Hylaform Plus (former three products manufactured by Inamed Aesthetics, Inc., Santa Barbara, CA).<sup>12</sup> We favor Restylane in our practice, primarily because of its superior durability in comparison to its counterparts. Clinical trials suggest that more than two-thirds of the initial correction produced by Restylane injection remains at 6 to 8 months after initial treatment.<sup>14</sup> Additionally, Restylane is derived from bacterial fermentation (versus chicken combs) and contains the highest concentration of hyaluronic acid (20 mg/mL) of the aforementioned fillers.

Nonanimal stabilized hyaluronic acid is generally safe. Special attention must be paid to individuals with extremely thin skin (i.e., elderly persons), as injections that are too superficial tend to cause lumping and the appearance of blue deposits. Furthermore, the use of hyaluronic acid during pregnancy and lactation has not been comprehensively evaluated and is therefore not recommended.<sup>12</sup>

### HUMAN-DERIVED COLLAGEN

As previously mentioned, the modern era of injectable filler use began with the advent of bovine collagen, which was approved by the FDA in 1981. Today, bovine-derived collagen is manufactured by Inamed, Inc. (Santa Barbara, CA) by the tradenames of Zyderm and Zyplast. Soft tissue augmentation typically lasts 3 months, although some reports have suggested moderately longer durability.<sup>14</sup> A limitation to the use of bovine-derived collagen as an injectable agent is its tendency to illicit hypersensitivity reactions in ~5% of patients. Therefore, two skin tests, performed at least 2 weeks apart, are required prior to injection to ensure patient safety.

In 2003, the FDA sanctioned the use of human-derived collagen (Cosmoderm and Cosmoplast, Inamed Corporation, Santa Barbara, CA) for the treatment of facial rhytids. Currently, these products are composed of 35 mg/mL of human-derived collagen in a phosphate-buffered physiological saline solution. Additionally, 0.3% lidocaine is incorporated into the injectate to provide for partial anesthesia during injections. In contrast to bovine-derived collagen, human-derived collagen carries essentially no risk of hypersensitivity reactions, obviating the necessity for pretreatment skin testing. Typically, injections maintain augmentation greater than 3 months.<sup>8</sup>

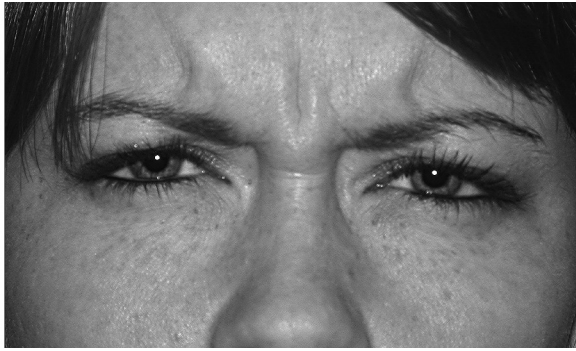Although human-derived collagen is well tolerated by patients, it is contraindicated in some cases. Specifically, it is not recommended for people with known allergy to bovine collagen or women who are pregnant. Patients with connective tissue disorders, such as rheumatoid arthritis or scleroderma, have an increased risk of hypersensitivity reactions. Additionally, its safety and efficacy in the use of lip augmentation has not been formally established. Finally, visible white areas in the skin may occur when the injectate is placed too superficially.<sup>15</sup>

### COMPLICATIONS

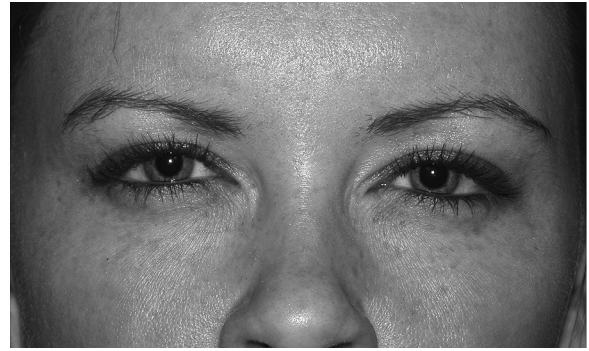Although uncommon, potential risks associated with the injection of dermal fillers can occur; therefore, it is incumbent upon physicians to counsel patients about potential complications. Excessive bleeding may occur; patients are instructed to refrain from medications and herbal supplements that impair clotting for 7 to 10 days prior to treatment. Infection can result after the third or fourth posttreatment day and once diagnosed should be treated promptly with antibiotics. For those patients who contract frequent cold sores, antiviral prophylaxis is recommended, specifically 1 g of valacyclovir (Valtrex, GlaxoSmithKline, Philadelphia, PA) prior to injection and another 1 g of valacyclovir 12 hours posttreatment. More serious complications from dermal filler administration are extremely rare but may include stroke, anaphylactic reactions, local skin necrosis due to occlusion of cutaneous arterioles, and death.<sup>8,12</sup>

### APPROACH TO THE UPPER THIRD

The primary objective in the management of the aging face with injectables is to attenuate wrinkles while maintaining patient facial animation. This is especially true when addressing the upper third of the face. To this end, we use the lowest effective doses of botulinum toxin type A and supplement residual lines with soft tissue fillers. Conceptually, botulinum toxin type A addresses wrinkles by relaxing the muscles responsible for their creation (i.e., the "dynamic" component), and soft tissue fillers provide necessary volume for effacement of facial



A



B

**Figure 1** A 27-year-old woman (A) prior to and (B) 2 weeks after treatment with a total of 25 U of botulinum toxin type A injected at five sites into the glabellar region.

rhytids (i.e., “static” component). We believe that such a complement of neurotoxins and fillers not only optimizes aesthetic outcomes but also preserves natural facial expression.

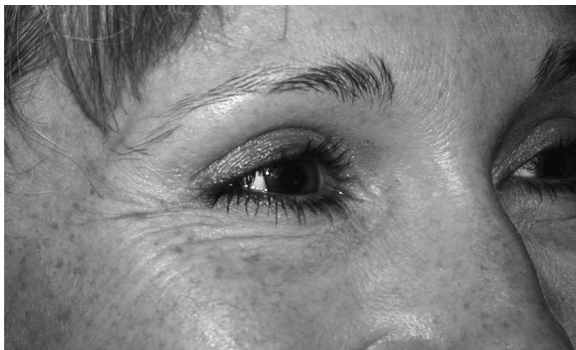Our treatment of glabellar lines involves injection of botulinum toxin type A to five sites: one injection into the procerus muscle at the midline and two injections into each corrugator supercilli muscle laterally. Total dosing in this region ranges from 25 to 30 U for women, and often larger doses ranging from 35 to 40 U are used to treat men (Fig. 1). Some patients who recruit the nasalis muscle when frowning will exhibit “bunny lines” at the level of the nasal radix. We treat these patients with 2.5 U of botulinum toxin type A, with injections to each superior sidewall of the nose, midway between the bridge of the nose and nasofacial groove.

Depending on the severity of rhytids, the forehead should be treated conservatively with doses of botulinum toxin type A ranging from 7.5 to 20 U in three to eight sites, depending on the horizontal length of the forehead. Critical to success in this area is placement of botulinum toxin type A injections superior to the “equator” of the forehead, defined by the imaginary horizontal line on the forehead that is equidistant from the trichion and the nasofrontal angle. This effectively preserves an inferiorly-based, 2- to 3-cm horizontal segment of the frontalis muscle. Preservation of this segment ensures maintenance of brow position (i.e.,

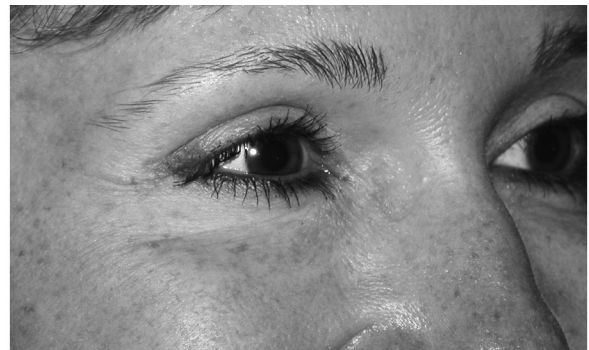prevents brow ptosis) and allows for continued facial animation postinjection. In addition, we inject laterally on the forehead to prevent unnatural elevation of the lateral brow (i.e., the “quizzical look”).

Periorbital “crow’s feet” are typically treated with a total of 10 to 15 U of botulinum toxin type A injected at three to six sites for each side (Fig. 2). Care must be taken to inject superficially to avoid the periorbital vasculature. Rhytids resulting from hypertrophic orbicularis oculi muscles, often referred to as “jelly rolls,” can be treated with 2 to 2.5 U of botulinum toxin type A at the midpupillary line below the ciliary margin. Patients who receive this treatment must have satisfactory lid tone (i.e., adequate “snap test” and “lid distraction test”).

Although botulinum toxin type A remains the primary injectable agent for the upper one-third of the face, supplementation with fillers can offer refinements in contour and wrinkle effacement. We frequently inject hyaluronic acid or cross-linked, human-derived collagen (Cosmoplast) into deeper rhytids of the glabella and forehead. For superficial lines, particularly in the crow’s feet region, we supplement botulinum toxin type A injections with non-cross-linked human-derived collagen (Cosmoderm). The “serial puncture” along with the “serial threading” techniques are utilized for placement of fillers at these sites. In addition, our experience suggests that pretreating rhytids with botulinum toxin type A significantly increases the longevity of soft tissue

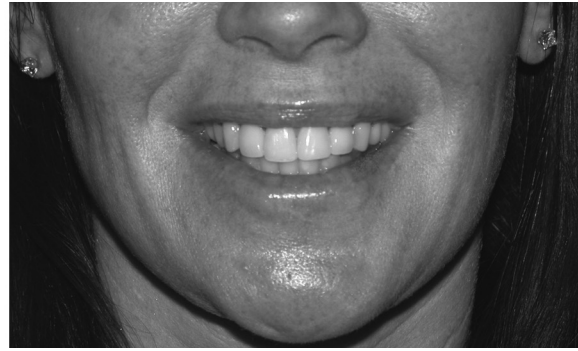
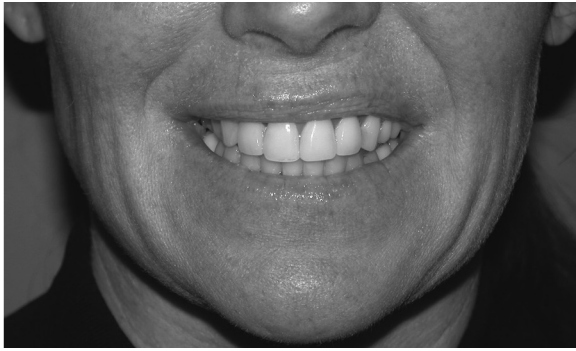
A



B

**Figure 2** A 52-year-old woman (A) prior to and (B) 2 weeks after treatment with 15 U of botulinum toxin type A injected at six sites per side into the crow’s feet region.



**Figure 3** A 33-year-old woman (A) prior to and (B) 2 weeks after treatment with botulinum toxin type A and hyaluronic acid. One milliliter of hyaluronic acid was injected into the nasolabial folds, and 2 U of botulinum toxin type A was injected at the apex of the right nasolabial fold to lower the right upper lip. The result is enhancement of the nasolabial folds and improved symmetry of the lips upon smiling.

fillers. This can be explained by the fact that dermal fillers exhibit greater durability at static sites. Therefore, by weakening muscle activity with botulinum toxin, these injectable agents tend to resorb less quickly.

### APPROACH TO THE MIDDLE THIRD

The middle one-third of the face is primarily treated with dermal fillers. However, as in the upper one-third of the face, synergism between filler and chemodenervation is still applicable. The nasolabial folds are best treated with hyaluronic acid and/or human-derived collagen. To achieve greater precision, the architecture of the nasolabial folds may necessitate the need for “layering” of hyaluronic acid on top of collagen. In this “two-filler” design, the foundation of the nasolabial folds is injected with hyaluronic acid. Human-derived collagen is then injected superficially to this foundation to “fine-tune” the nasolabial crease. Additionally, botulinum toxin type A may be used with caution in the nasolabial region. Low dosing (~1 to 2 U per side) and meticulous placement in the apex of the nasolabial folds is the rule. Otherwise, ptosis of the upper lip may occur when smiling. Therefore, patients with excessive gingival show (i.e., a “gummy smile”) may be best suited for this treatment. In fact, there may be a potential benefit to dropping the upper lip in these patients (Fig. 3). Alternatively, patients who have minimal “tooth show” when

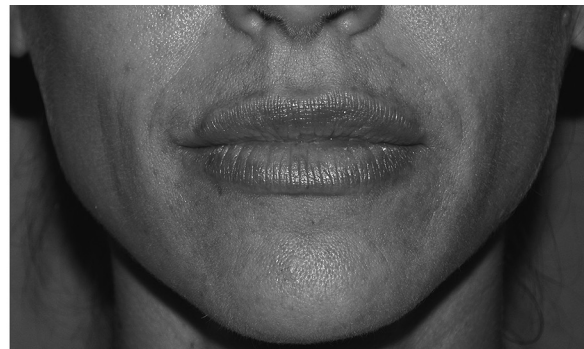
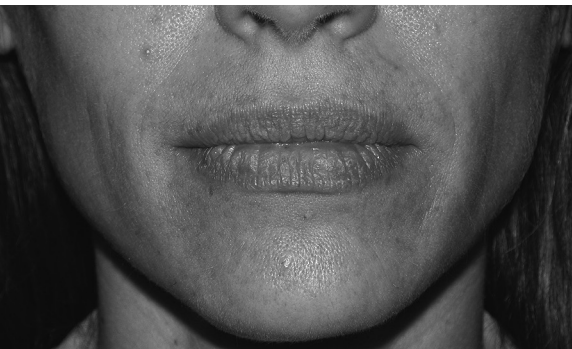
smiling represent unfavorable candidates for botulinum toxin type A in this region, due to the risk of exacerbating their condition.

We have found that dermal fillers are useful for temporary correction of midface ptosis and volume loss, especially in patients who are considering more involved procedures, such as rhytidectomy or midfacelift surgery. Augmentation with hyaluronic acid, using the “cross-hatching” injection technique, can provide necessary structure to the cheek region for improved appearance and can serve as a “rehearsal” for future surgical augmentation.

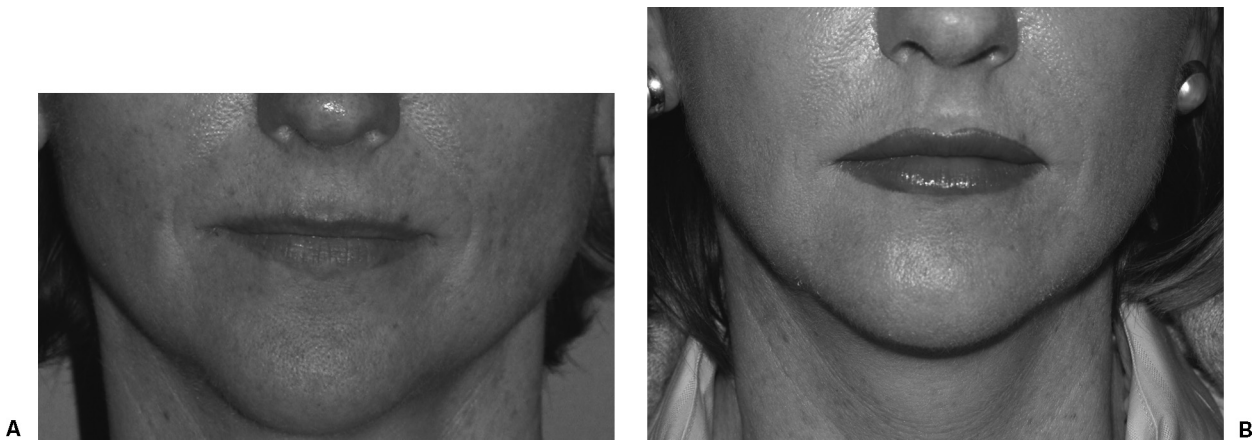
### APPROACH TO THE LOWER THIRD

Temporary fillers are used in our practice to augment the lips. Three aspects of lip aesthetics are considered: (1) definition of the vermilion border, (2) fullness, and (3) poutiness. We inject hyaluronic acid for augmentation and occasionally use non-cross-linked, human-derived collagen, injected by “serial puncture” and “serial tracking techniques,” to highlight the vermilion border. Fullness is created by injecting the tubercles (three sites for upper lips and two sites for lower lips). To achieve poutiness, hyaluronic acid is injected above the gingivo-labial sulcus to create eversion of the upper and lower lips (Fig. 4).

Perioral lines are optimally treated with fillers, specifically human-derived collagen for fine lines and



**Figure 4** A 37-year-old woman (A) prior to and (B) 2 weeks after augmentation of the upper and lower lips with 1.5 mL of hyaluronic acid.



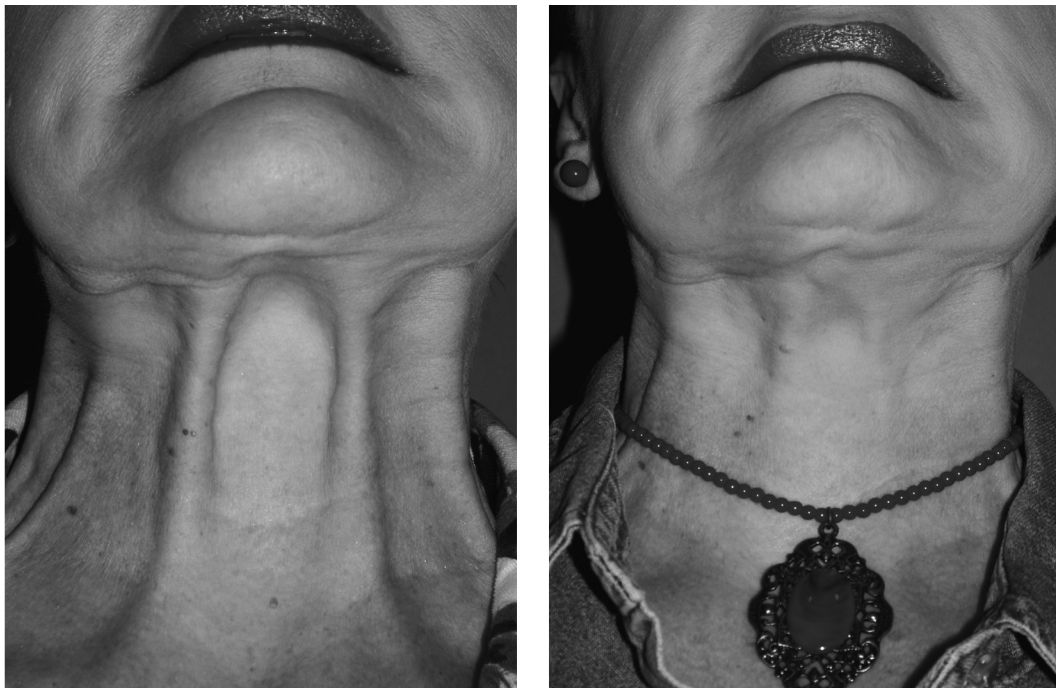**Figure 5** A 48-year-old woman (A) prior to and (B) 2 weeks after treatment of the lower third of face with injectables. Hyaluronic acid was injected into the prejowl sulci, nasolabial folds, marionette lines, and upper and lower lips. Additionally, 3 U of botulinum toxin type A was injected into the depressor anguli oris muscles to improve the downturn of the oral commissure.

hyaluronic acid for deeper rhytids. Botulinum toxin type A in low doses may complement volume augmentation. Approximately 1 to 2 U in each of the four lip quadrants along the vermilion border are injected. Implementing both techniques softens lines in this region and is helpful in the prevention of “lipstick bleeds” in female patients.

The marionette region is also amenable to fillers and, to some extent, botulinum toxin type A. These folds require structured dermal support for optimal results, making hyaluronic acid ideal for this region. Fine lines in this area may be improved with human-derived collagen. To supplement fillers, 3 to 5 U of botulinum toxin type A placed into the depressor anguli oris muscle along the

mandible, just anterior to the border of the masseter muscle, can help to improve the downturn of the oral commissure. In addition, hyaluronic acid placed in the prejowl sulcus can improve the jawline in younger patients starting to develop early jowl formation (Fig. 5).

The irregular contours of the chin (i.e., “peau d’orange” or “cobblestoning”) may benefit from fillers, as well as botulinum toxin type A. These irregularities occur secondarily to dermal and subcutaneous atrophy and are often affiliated with acne scarring. Therefore, they are amenable to hyaluronic acid augmentation. Furthermore, contraction of the mentalis muscle can exacerbate this “peau d’orange” appearance. Accordingly, 8 to 10 U of botulinum toxin type A injected into the



**Figure 6** A 68-year-old woman (A) prior to and (B) 2 weeks after treatment with 30 U of botulinum toxin type A injected at six sites per side for correction of platysmal bands.

mentalis muscle in divided doses at the lower aspect of the chin may be of benefit.

In the neck region, platysmal banding can be addressed with 2.5-U injections of botulinum toxin type A, placed every 1.5 cm along the bands (Fig. 6). Thin necks with little submental adiposity respond well to this treatment. In addition, minor platysmal banding that occasionally results from neck rejuvenation surgery can be corrected with adjuvant botulinum toxin type A injections, using a similar technique.

### SUMMARY AND CONCLUSIONS

The objective of this article was to provide an overview of the injectables that are currently available to the facial plastic surgeon for management of the aging face. In selected patients, these agents serve as powerful tools in treating two hallmarks of facial aging, namely dynamic wrinkles and subcutaneous volume loss. A thorough understanding of these products, including their composition, safety profiles, benefits, and limitations, is critical to achieving successful outcomes. We have outlined a systematic approach to treating each subunit of the aging face, with particular emphasis on the synergistic effect that can be obtained from the concomitant use of neurotoxins and soft tissue fillers.

### REFERENCES

1. Cosmetic Surgery National Data Bank Statistics 2005. New York: American Society for Aesthetic Plastic Surgery; 2005
2. Scott AB. Botulinum toxin injection into extraocular muscles as an alternative to strabismus surgery. *Ophthalmology* 1980; 87:1044-1049
3. Blitzer A, Binder WJ. Cosmetic uses of botulinum neurotoxin type A: an overview. *Arch Facial Plast Surg* 2002;4: 214-220
4. Carruthers J, Fagien S, Matarasso SL; Botox Consensus Group. Consensus recommendations on the use of botulinum toxin type A in facial aesthetics. *Plast Reconstr Surg* 2004; 114(Suppl.):1-22
5. Blitzer A, Sulicia L. Botulinum toxin: basic and science and clinical uses in otolaryngology. *Laryngoscope* 2001;111:218-226
6. Meyer KF, Eddie B. Perspectives concerning botulism. *Z Hyg Infektionskr* 1951;133:255-263
7. Matarasso SL. Complications of botulinum A exotoxin for hyperfunctional lines. *Dermatol Surg* 1998;24:1249-1254
8. Sengelmann RD. Dermal fillers. *E-Medicine*; February 7, 2006
9. Cooperman LS, Mackinnon V, Bechler G, et al. Injectable collagen: a six-year clinical investigation. *Aesthetic Plast Surg* 1985;9:145-151
10. Tzikas TL. Evaluation of the Radiance FN soft tissue filler for facial soft tissue augmentation. *Arch Facial Plast Surg* 2004;6:234-239
11. Nakagawa M, Tanaka M, Miyata T. Evaluation of collagen gel and hyaluronic acid as vitreous substitutes. *Ophthalmic Res* 1997;29:409-420
12. Balazs EA, Denlinger JL. Clinical uses of hyaluronon. *Ciba Foundation Symposium* 1989;143:265-275
13. Hascall VC, Laurent TC. Hyaluronan: structure and function. <http://www.glycoforum.gr.jp/science/hyaluronan/HA01/HA01E.html>. Accessed April 25, 2006
14. Narins RS, Brandt F, Leyden J, et al. A randomized double-blind, multicenter comparison of the efficacy and tolerability of Restylane versus Zyplast for the correction of nasolabial folds. *Dermatol Surg* 2003;29:588-595
15. Inamed Aesthetics. Cosmoderm and Cosmoplast: human-based collagen explained. <http://www.inamed.com>. Accessed April 26, 2006